


# IBB 2022

Additional Learning Resource:

## Neuroanatomy



**Charles Watson**

Matthew Kirkcaldie, Friedrich Schwarz

April 2022

**AN INTRODUCTION TO THE ANATOMY OF THE CENTRAL NERVOUS SYSTEM 1**

Introduction 1

**DEVELOPMENT OF THE NERVOUS SYSTEM 4**

The development of the nervous system 4

**THE SPINAL CORD 14**

Spinal Cord 14

**THE BRAIN STEM 22**

Brain stem 22

The brain stem cranial nerves 32

The cerebellum 36

**DIENCEPHALON 40**

The diencephalon 40

**HYPOTHALAMUS 42**

The hypothalamus 42

**Telencephalon 46**

The Telencephalon 46

The Brodmann areas of the cortex 51

**MOTOR SYSTEMS 53**

Motor systems 53

**SENSORY SYSTEM 59**

The somatosory system 59

The visual system 63

The auditory system 66

The vestibular system 69

Olfaction 73

Taste 77

**THE AUTONOMIC NERVOUS SYSTEM 79**

The autonomic nervous system (ANS) 79

**BLOOD SUPPLY TO THE BRAIN 82**

The blood supply to the brain 82

**THE CIRCULATION OF CEREBROSPINAL FLUID 85**

The cerebrospinal fluid and its circulation 85

**STAINING AND IMAGING 87**

Staining and imaging - Fundamentals 87

# AN INTRODUCTION TO THE ANATOMY OF THE CENTRAL NERVOUS SYSTEM

## Introduction

This introduction is a very brief summary of the parts of the central nervous system and their functions. You may find it helpful to have this basic information before you begin a detailed study of the parts of the brain.

The central nervous system consists of the brain and the spinal cord. The spinal cord is relatively simple in structure, but the brain is very elaborate. The main parts of the brain are the brain stem, cerebellum, and forebrain.

The brain and spinal cord are connected to parts of the body by nerves. These nerves are both sensory and motor. There are 12 pairs of nerves connected to the brain (the cranial nerves) and 32 pairs of nerves connected to the spinal cord (the spinal nerves).

The functions of the central nervous system are arranged hierarchically, with the simplest functions (like standing and walking) located in the spinal cord and the most sophisticated functions (like thinking and memory) located in the forebrain. In between, the brain stem is responsible for survival functions like breathing, eating, vocalisation, and balance. The advantage of this hierarchical arrangement is that complex functions are pre-packaged in the brain stem and spinal cord; they act as complete functional modules, ready to respond to commands from the forebrain.

## The spinal cord

In older times, the spinal cord was pictured as a simple sensory receiving station with simple connections to the muscles and internal organs. These facts are still partially true, but they only tell part of the story. For example, the spinal cord action modules can control whole movement patterns, not just connections to single muscles. More than that, it can coordinate muscle activity involved in walking, standing, balance, and reaching and grasping. The remarkable control of the spinal cord can be seen in animals like horses that are able to stand and move around within minutes of being born because these functions are already pre-programmed in the spinal cord.

The wiring of the spinal cord enables it to respond to some sensory signals in a rapid reflex way before the brain is even aware of the sensory signal. A prime example is when we step on something sharp with bare feet. The spinal cord causes the lower limb to flex and pull away from the sharp object. At the same time, it causes the extensor muscles in the opposite lower limb to contract in order to stop you from overbalancing.

The spinal cord is strongly connected to the internal organs and blood vessels through nerves that are called autonomic. Autonomic nerves control the workings of blood vessels and the internal organs like the intestines and bladder. Some of these functions, but not all, can be controlled by the forebrain through its connections with the spinal cord. The autonomic nerves connected to the thoracic spinal cord are called sympathetic nerves, and those connected to the sacral spinal cord are called parasympathetic nerves.

## The brainstem

The brainstem connects the spinal cord with the forebrain. It is the home of basic functional systems that are vital for survival. These include breathing, chewing, swallowing, vocalisation, facial expression, and eye muscle control. As well as the control of these actions, the brainstem receives sensory information related to taste, hearing, vision, the skin of the face,

and balance. The brainstem is also a corridor through which pathways (tracts) travel from the forebrain to the spinal cord, and from the spinal cord to the forebrain. It also contains centres that send pathways to keep the forebrain awake and alert.

The brainstem can be divided into two parts: the hindbrain (connected to the spinal cord) and the midbrain (connected to the forebrain). Each of these parts gives rise to important expansions on the dorsal surface. The dorsal surface of the hindbrain gives rise to the cerebellum, and the dorsal surface of the midbrain gives rise to two pairs of bumps – the superior and inferior colliculi. The superior colliculi are visual centres, and the inferior colliculi are auditory centres.

## The cerebellum

As we have just noted, the cerebellum grows out of the hindbrain. It is formed from the top end of the hindbrain, just behind the midbrain. The cerebellum is tiny at birth, but it learns to coordinate complex movements during the next five years and beyond. The cerebellum contains an enormous number of tiny neurons called granule cells involved in learning coordination. Almost 80% of all the neurons in the brain are found in the cerebellum.

## The forebrain

The forebrain has a central part that continues the brain stem, and a massive outgrowth on each side called the cerebral hemisphere.

## Thalamus and hypothalamus

The smaller central part of the forebrain is made up of two main structures, the thalamus and the hypothalamus. The thalamus receives sensory pathways related to touch, taste, hearing, vision, and balance and sends this information to the cerebral hemisphere. The hypothalamus is the centre for high-level control of the functions that ensure the survival of the individual and the species. Survival of the individual depends on eating and drinking and being able to defend itself, and survival of the species depends on reproduction and care of offspring. The hypothalamus carries out these functions by controlling the survival modules in the brain stem and spinal cord and controlling the endocrine and autonomic nervous systems.

## The cerebral hemisphere

The cerebral hemisphere consists of an outside layer called the cerebral cortex and a number of deep neuron groups called the basal ganglia. In the human brain, the cerebral cortex undergoes massive expansion, which results in deep folding that forms sulci and gyri on the surface. The cerebral cortex is subdivided into about 180 distinct areas, but we only know the precise functions of some of these areas. However, we do know a lot about the total functions of the cerebral cortex and it is useful to remember these under eight headings:

- senses
- actions
- thinking
- memory
- communication
- emotions
- sleep and alertness
- relationship

Each of these functions can be subdivided. For example, 'senses' includes touch, taste, hearing, vision, smell, and balance, and 'thinking' includes planning, decision making and problem-solving. Combinations of these eight functions give humans higher-level skills such as creativity, inventiveness, social organisation, and learning.

### *The basal ganglia – striatum, pallidum, and amygdala*

The cerebral hemisphere's deep (non-cortical) parts include several structures, sometimes collectively referred to as the basal ganglia. This term is not entirely satisfactory but can be used as a shorthand. The larger parts of the basal ganglia are the striatum and pallidum, which are involved in inherited and learned motor functions. When these areas are damaged during late pregnancy, the child may develop cerebral palsy – a complex combination of muscle stiffness and involuntary movements. A smaller member of the non-cortical structures is the amygdala, which plays a vital role in emotional responses (particularly fear) and social group behaviour.

### Questions for repetition

- What is the central nervous system consisting of?
- How many spinal nerve pairs are there?
- In which part of the brain are the most neurons?
- What parts of the autonomic nervous system exist?

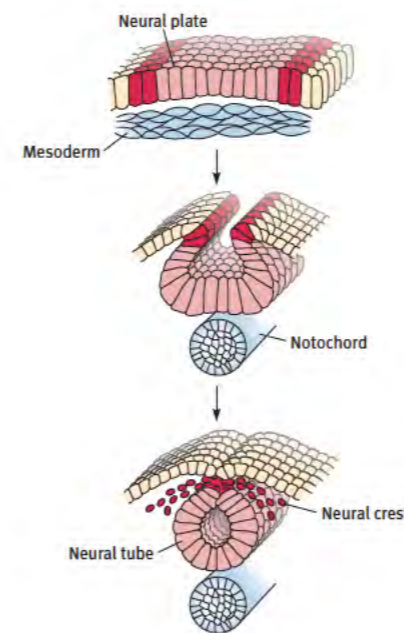
## DEVELOPMENT OF THE NERVOUS SYSTEM

### The development of the nervous system

About 14,000 genes control the development of the brain in mammals, more than half of the total number of genes. The genes first provide the general instructions for building connections in the brain, but later organise the unique connection patterns that characterise each brain region.

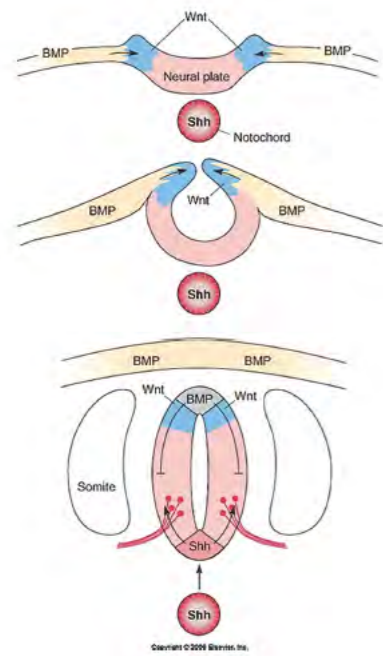
### Dorsal and ventral specification of the cells in the neural tube

The embryonic brain develops from a strip of ectodermal cells that form the neural plate. The edges of the neural plate curl medially to join and form the neural tube, which encloses the neural canal.



***This series of diagrams shows the formation of the neural tube from the embryonic neural plate. Under the influence of secreted factors from the notochord, the cells of the neural plate sink down to form a groove and the edges of the groove (red) join to form the neural tube. The edges of the groove form the cells of the neural crest, which migrate away from the neural tube to form ganglia, melanocytes, and the skeleton of the face. Figure from Sanes et al. 2004, courtesy of Dr. Dan Sanes, New York University.***

At this early stage, the cells dorsal to the neural canal are directed by *Wnt* and *BMP* genes to form the two alar plates (which handle sensory functions). In contrast, the cells ventral to the central canal are directed by sonic hedgehog (*Shh*) genes to form the two basal plates (which are oriented toward motor functions).



As the neural tube forms from the neural plate, its development is influenced by the expression of a gene called sonic hedgehog (Shh). Expression of Shh in the notochord induces the development of the ventral structures (such as motor neurons) in the neural tube. The dorsoventral patterning of the neural tube is created by the opposing influences of Shh (ventrally) and BMP and Wnt genes (dorsally). Figure from Sanes et al. 2004, courtesy of Dr. Dan Sanes, New York University.

As the neural tube closes, a scattering of cells breaks away from the dorsal side to form the neural crest, which gives rise to the peripheral nervous system, melanocytes, bones and muscles of the face.

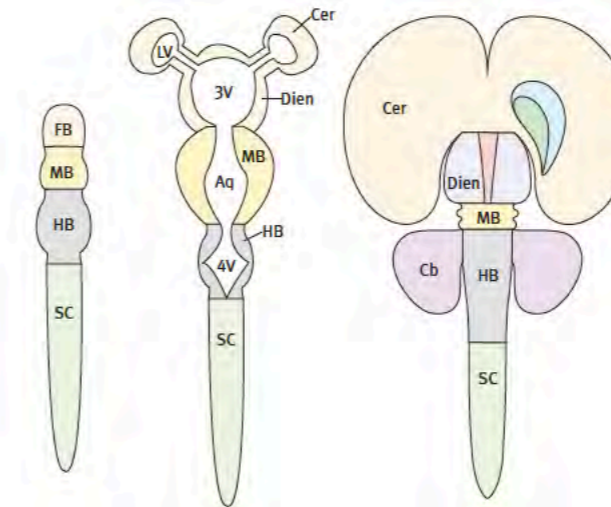
#### Brain vesicles

As cells divide, the rostral end of the tube develops three swellings called the forebrain, midbrain, and hindbrain vesicles. The central part of the forebrain vesicle gives rise to two extensions, the lateral vesicles, subsequently forming the cerebral hemispheres. The roof of the midbrain vesicle (the tectum) gives rise to four swellings that go on to form the superior and inferior colliculi. The roof of the rostral part of the hindbrain vesicle forms the cerebellum.

The small group of embryonic cells that forms the neural tube quickly multiply and specialise to form specific functional centres in the brain. The multiplication rate is extraordinary and the few hundred cells in the primitive human neural tube eventually generate over 80 billion nerve cells. During the first two years of life, there are times when up to 250,000 new cells are generated every minute.

#### Segmentation in the brain

Towards the end of the nineteenth century, several embryological studies found evidence of segmental subdivisions in the brain, which Orr (1987) called neuromeres. Unfortunately, the concept of brain segmentation was largely ignored for the next hundred years, before being spectacularly confirmed by the new science of gene expression in the developing brain, following the discovery of gene targeting in mice by Mario Capecchi (1989). Since then, many studies of gene expression in the developing vertebrate brain have confirmed that the brain is made up of a series of distinct neuromeres (Puelles et al., 2013; Watson et al., 2017b): five in the forebrain, two in the midbrain, and twelve in the hindbrain. Each segment is made up of alar and basal components around the neural canal.



At the rostral end of the neural tube, three expansions appear - the forebrain, midbrain and the hindbrain vesicles. The forebrain vesicle forms the cerebral hemispheres, the diencephalon, the hypothalamus, and the eye stalk. The hindbrain forms the isthmus, the rhombencephalon, and the cerebrum.

The primary division in the neural tube is the separation of the forebrain and midbrain on the one hand and from the hindbrain on the other. This separation is defined by the expression of Otx2 in the forebrain and midbrain and the expression of Gbx2 in the rostral hindbrain. The expression pattern of Otx2 has led to the proposal that the midbrain segments be declared part of the forebrain.

#### Hypothalamic segments and the formation of the telencephalic vesicle and the optic vesicle

The five forebrain segments consist of the terminal hypothalamus (hy2), the peduncular hypothalamus (hy1), and three diencephalic segments called prosomeres (p1, p2, and p3). The terminal hypothalamic segment (hy2) is the rostral end of the neural tube. It gives rise to the telencephalic (cerebral) vesicles dorsally and the optic vesicles rostrally, as well as the posterior lobe of the pituitary (neurohypophysis).

The telencephalic vesicle is layered: the surface layer is the pallium, and beneath is the subpallium, which splits into four divisions - the striatum, pallidum, the diagonal domain, and the preoptic area.

#### Diencephalic segments

The three diencephalic segments, from rostral to caudal, are prosomere 1 (mainly the prethalamus), prosomere 2 (mainly the thalamus), and prosomere 3 (mainly the pretecal area). The pineal gland grows dorsally from p2, and the posterior commissure is found in p3. Although the diencephalon forms caudally to the hypothalamus, the neuraxis becomes sharply flexed during development, pushing the hypothalamus into a final ventral position under the prethalamus. This gave the impression that the hypothalamus was a ventral component of the diencephalon, as it was wrongly assumed in an older concept thereof, including the thalamus.

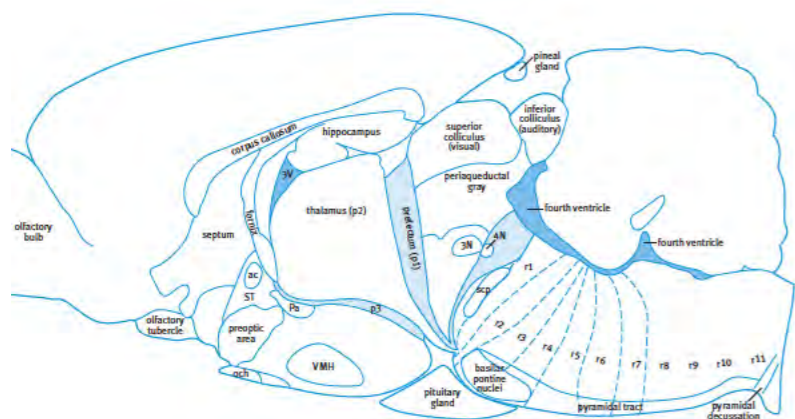
#### Midbrain segments

The midbrain consists of a large rostral segment (m1) and a much smaller caudal segment (m2). The dorsal surface of m1 forms the superior colliculus and inferior colliculus on each side. In the past, the pretecal segment of the diencephalon (including the posterior commissure) was mistakenly thought to belong to the midbrain. Additionally, the first segment of the hindbrain, the isthmus, was also mistakenly thought to belong to the midbrain, but gene ex-

pression proves it is not. The sharp bend of the neuraxis at the level of the midbrain (the cephalic flexure) results from the under-development of the ventral surface but leaves the dorsal surface intact. This creates a heart-shaped profile in sagittal sections.

### Hindbrain segments

The hindbrain is made up of the isthmus and eleven rhombomeres (r1 to r11). In older textbooks, the isthmus, which contains the trochlear nucleus, was sometimes called rhombomere zero (r0). The dorsal parts of the isthmus and rhombomere 1 give rise to the cerebellum. The pontine nuclei are formed on the ventral surface of rhombomeres 3 and 4.



**This is a diagram of an adult rodent brain showing the position of the segments of the hindbrain. The embryonic hindbrain contains twelve compartments from rostral to caudal. The first compartment, adjacent to the midbrain is called the isthmus. The remaining eleven compartments are called rhombomeres. Rhombomeres 2 to 11 are defined by the expression of different *hox* genes. The isthmus is defined by the expression of *fgf8*. The cerebellum is formed by extensions of the isthmus and the first rhombomere.**

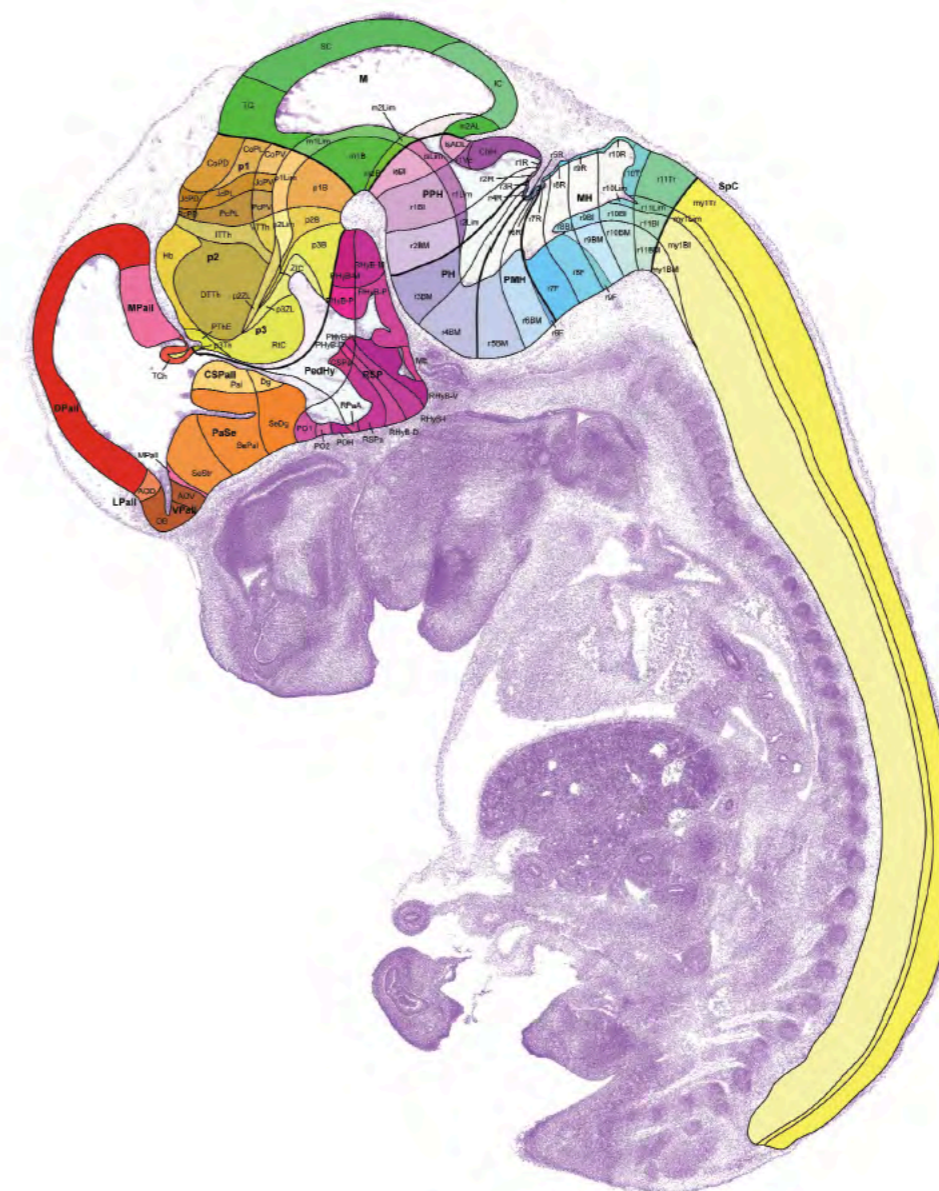
The genes responsible for creating the majority of the rhombomeres (r2 to r11) are the homeobox (*hox*) genes. The *hox* genes, discovered initially in developing insects, are also universally important for nervous system development in vertebrates. The first four *hox* groups (*hox1-hox4*) are expressed in the hindbrain, and *hox5-hox13* are expressed in the spinal cord, trunk, limbs, and tail.

The *hox* genes are not expressed in the isthmus and in the first rhombomere, which instead express *Gbx2*, further subdivided by *Fgf8* expression in the isthmus.

The neural canal of the hindbrain opens up dorsally to form the fourth ventricle, with a thickened lateral margin called the rhombic lip.

### Flexion of the neural tube

As mentioned above, the neural tube does not remain straight during development. Because of differential dorsal and ventral growth in some areas, the tube forming the brain is forced into flexion at two points. The most significant of these is the cephalic flexure in the midbrain region. It is so severe that it creates almost a 180-degree bend in the neuraxis and pushes the hypothalamus ventral to the diencephalon. A second, less severe flexion is found in the hindbrain.



**This is a photograph of a sagittal section of a mouse embryo (E13.5) with an overlay showing the subdivisions of the developing nervous system. The image is taken from the reference atlas developed by Luis Puelles as part of the Allen Developing Mouse Brain Atlas created by the Allen Institute for Brain Science.**

Lack of appreciation of the significance of the cephalic flexure has led to tragic misinterpretation of the relationships between parts of the forebrain, particularly the belief that the hypothalamus is simply some kind of ventral addition to the thalamus.

### Regionalisation in the spinal cord

The spinal cord is traditionally divided into a number of segments related to the emergence of individual spinal nerves. The presence of a vertebra between each pair of spinal nerves gives the impression that the spinal cord is a segmented structure, but this is an illusion, and the roots of the spinal nerves run in a continuous strip along the cord inside the vertebral canal. On the other hand, there is clear evidence from anatomical and *hox* gene expression studies that the spinal cord of four-limbed vertebrates can be divided into six distinct functional regions - prebrachial (C1-C4), brachial (C5-T1), postbrachial ((T2-L1), crural (L2-S1), postcrural (S2-S4), and caudal (S5-Co2). The brachial and crural regions contain the motor neurons

that supply the limb muscles of the upper and lower limbs, respectively. The postbrachial and postcrural parts contain the preganglionic neurons of the sympathetic and spinal parasympathetic systems, respectively. The prebrachial region contains the motor neurons supplying the cervical muscles, and the caudal region contains motor neurons supplying the tail muscles.

#### Neural crest

Just after the closure of the neural tube, a group of cells migrates away from the dorsal surface of the neural tube to form a column on either side, called the neural crest. The neural crest cells give rise to both neurons (the ganglion cells of the autonomic nervous system and the sensory dorsal root ganglion cells of cranial and spinal nerves) and non-neural elements such as the melanocytes of the skin and (surprisingly) the bones and muscles of the face. The melanocytes migrate long distances to reach all areas of the skin surface.

#### Development of the peripheral nervous system

The peripheral nervous system is made up of three components – the axons of motor neurons that connect to muscles, the dorsal root ganglion cells and their long axons, which reach sensory receptors, and the ganglia and postganglionic axons of the sympathetic and parasympathetic ganglion cells. It is important to note that the optic and olfactory nerves are not part of the peripheral nervous system since they are direct outgrowths of the forebrain, with myelin produced by oligodendrocytes instead of Schwann cells.

The elements of the peripheral nervous system are primarily distributed by cranial nerves 3-12 and by the spinal nerves. In both cranial and spinal nerves, the axons of motor neurons grow out until they reach their target muscle.

#### Adult neurogenesis

Some parts of the mature mammalian brain, notably the hippocampus, the cerebellum, and the olfactory bulb, can actually generate new neurons. In most other areas of the brain, it seems neuroplasticity appears to be solely the result of the massive reorganisation of synaptic networks in response to new demands.

#### Migration of neurons

In many parts of the brain, neurons continue to develop in the place where they were first formed. These neurons may send their axons to other areas in the brain, but the neuronal cell bodies do not move. However, in a few places in the brain, groups of neurons migrate from their place of birth to reach their final location. In the cerebral cortex, most neurons are generated at the surface of the ventricle and migrate outward to find the cortical layer in which they will finally reside. Most of the neurons that migrate toward the surface of the brain (radial migration) are the future pyramidal and stellate neurons of the cortex, both of which are excitatory glutamatergic neurons. On the other hand, the small GABAergic inhibitory neurons of the cortex arise in the base of the forebrain and migrate tangentially to reach their final settlement in the cortex, so the final structure is the product of large migrations moving at right angles to each other. The GABA neurons constitute 20% of the cortical neurons in mammals.

The largest migration of neurons in the brain begins in the rostral part of the rhombic lip, which borders the rostral end of the fourth ventricle of the hindbrain. Most of the rhombic lip cells migrate dorsally into the developing cerebellum, while smaller numbers migrate ventrally into the longitudinal part of the hindbrain. Those that migrate into the cerebellum form the tiny granule cells that eventually make up 70% of all the neurons in the brain. Because of this, the rhombic lip is now recognised as the most active cell generation area in the developing nervous system.

The wide dispersal of neurons and melanocytes from the neural crest constitutes another major neural migration during development. The process by which the crest cells detach and move through tissue involves many genes, some of which are implicated in cancer metastasis.

#### Formation of synapses

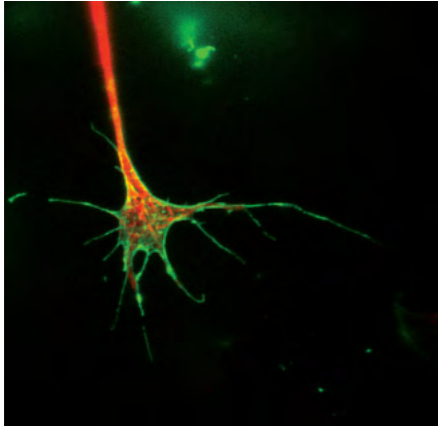
Developing neurons sprout thin outgrowths called processes, which connect with other nerve cells or muscle cells. The connections they make, generally between an axon process on the sending side and a dendrite process on the receiving side, are called synapses. Much of the basic wiring of the brainstem and spinal cord is laid down early in fetal development. These early connections are those required for survival as they control breathing and swallowing. There is no room for error here, and these vital connections are formed according to a strict program. The first movements of the fetus early in pregnancy in humans are clear evidence of the formation of early connections between neurons and muscle cells. In mice, the connections with muscles are made after only 12 days of embryonic development, but these connections are not made until about 12 weeks in humans.

The second category of connections starts late in fetal development and extends into childhood and adult life. These later connections are less rigidly programmed, and they are made while the newborn mammal interacts with its environment and is learning new skills. The period in which this type of plasticity is most active is termed the "sensitive period" for sensory and motor systems and includes a shorter "critical period" during which the fundamental organisation is determined. It was formerly believed that the formation of new connections stopped sometime soon after birth, but it is now known that new connections are a normal part of the growth of all brains throughout life. The ability of the brain to constantly form new connections and to reshape patterns of connection in response to new information is referred to as plasticity. The plasticity of the human brain is remarkable. It has been estimated that the brain forms an average of a million new connections per minute throughout the whole of life.

#### Axon guidance

An axon that grows out from a neuron will only be functionally successful if it connects with the correct target cell. The mechanism that helps it find its correct target is called axon guidance, or axon pathfinding. Many growing axons have been found to be extraordinarily accurate in finding the right path to their target. In some cases, the axons neurons find their proper partner because they stick to matching molecules on the surface of other axons or have receptors sensitive to molecules made by their targets, which are both controlled by a common gene. For example, motor neuron clusters in the spinal cord and the muscle group to which they connect have been shown to share a specific gene marker. Axon guidance works by a process of stepwise refinement: First, the growing axon follows a general pathway, bundling with similar axons and obeying general routing cues (to which it may or may not be sensitive) such as crossing the midline. Then upon nearing its destination, it detects more specific chemical signals from its target. A gene pairing system like this, encoding attractant molecules and the receptors which respond to them, also exists in the hindbrain neuron groups that connect to particular cells in the cerebellum.

Whatever the mechanisms, the formation of early connections is remarkably accurate and reliable, so that brains are always initially wired up in the same way. The growing axon's tip is a very active enlarged area called a growth cone. The growth cone is a highly mobile structure that appears to feel its way through tissue, detecting very faint chemical signals that lead it towards its targets or which steer it away from unwanted connections. The signs may be fixed in place, like signposts, or may be distributed over long distances, like the breadcrumbs left behind by Hansel and Gretel.



*A growth cone at the tip of an axon from a rat dorsal root ganglion neuron in cell culture. Staining for actin (green) outlines the flattened lamellipodium, with numerous fine filopodia extending to explore the environment. Microtubules (red) fill the axon and extend into the central lamellipodium, the site of active growth. In vivo, the growth cone would have a three-dimensional ruffled shape. Image courtesy of Michael Thompson and Dr. Lisa Foa, University of Tasmania, Australia.*

At the stage when neurons are maturing and sending out axons to make contact with other neurons, the developing nervous system secretes a tapestry of guidance molecules that attract and repel, defining pathways, marking crossing points, and identifying destinations. Growing axons explore this space with their growth cones, responding to some cues and ignoring others, according to the receptors they carry. Axons from diverse regions converge on shared pathways and then branch out to distinct targets as they encounter individual cues. Several guidance molecules have been identified, and their functions have been analysed in detail; they include netrins, semaphorins, and Slit proteins. Once they reach their targets, axons stop growing because they encounter cell surface molecules that turn off growth and stimulate synaptic formation.

These stop signals vary in concentration, so arriving axons may fan out across the target tissue in an organised gradient. In the case of ephrins and Eph receptors, some axons will have few Eph receptors, and some will have many. If they encounter a tissue with a gradient of ephrins expressed, axons with many receptors will stop responding to small concentrations of ephrins. In contrast, those with few receptors will push past low-ephrin areas and stop when the ephrins become more concentrated. Since the Eph receptors and ephrins are regulated by genetic gradients in the target and the origin of the axons respectively, this simple mechanism preserves topographic arrangements across long distances.

#### Synapse pruning and nerve cell death

Not all of these new connections work as well as they should, and millions of synapses are pruned during early brain development so that the mature systems formed are accurate and efficient. In general, most systems follow a pattern of being over-connected initially, which is then refined by pruning, which continues throughout life. The same pruning process is applied to neurons: many are killed off during development, specifically those that have made poor connections or are otherwise unnecessary. These waves of synaptic pruning and neuronal death are part of the process of building an efficient nervous system. As with synapses, the pruning of cells and axon branches continues throughout life.

#### Critical periods in fetal development

Certain developmental insults can cause devastating damage to the developing brain and spinal cord. These include vitamin deficiency (neural tube defect), alcohol (fetal alcohol syndrome), iodine deficiency, and infections (rubella). Each one of these can cause widespread

damage to the fetal brain. It is possible that viral infections may also cause cerebral palsy during pregnancy.

Neural tube defects (NTD), the most common of which is called spina bifida, are caused by a disruption of the very early development of the neural tube, with incomplete closure at the rostral and/or caudal ends. The most common place for incomplete closure is in the caudal part of the spinal cord, and in the most severe cases, the damage to the spinal cord results in paralysis of the lower limb and loss of control of the bladder and bowel. Some families have a genetic predisposition to NTD, but the most critical factor is a lack of the vitamin folate. Since the risk period occurs before apparent signs of pregnancy, all women who might become pregnant should make sure that their folate intake is high—either by eating leafy vegetables and other folate-rich foods or by taking folate vitamin tablets as well a supplement. In many countries, bread flour and breakfast cereals are enriched with folate to ensure that the whole population has adequate folate levels.

Alcohol consumption by women in the first eight weeks of pregnancy can have devastating effects on early brain development, and the child may be born with significant deficiencies in brain function. The condition is called fetal alcohol syndrome.

Within the first three months of pregnancy, rubella infection (German measles) can cause major brain abnormalities, including deafness and blindness.

In the West, it is not widely appreciated that iodine deficiency during fetal development is the most important cause of intellectual disability worldwide. But it is still affecting millions of children in mountainous areas of Asia, Southeast Asia, and south-eastern Australia, where iodine has been leached out of the soil. Iodine deficiency results in hypothyroidism that permanently damages the developing brain by affecting key genes for connectivity. The problem of iodine deficiency is easily remedied with the supply of iodine supplements in salt and oil, but this is not always easy to achieve because of logistic impediments.

#### Critical periods during postnatal development

More than sixty years ago, it was shown that kittens that had one eye kept closed during a particular period after birth were unable to develop binocular vision subsequently. This led to a theory that one must receive a specific sensory input within a limited period for a part of the brain to develop normally. This concept had a major impact on theories of postnatal development. In particular, it raised serious concerns that children deprived of a particular stimulus or environment for a short period in their life might be deprived forever of some vital capability. However, this view has not been supported by contemporary evidence, and it is now felt that the concept should be applied more loosely. The modern version of this concept argues that critical periods are the ideal time for most children to receive a particular input. However, it accepts that delayed inputs can still be effective. For this reason, the term 'sensitive periods' is commonly used to denote longer time intervals during which experience can shape the nervous system. Sensitive periods during human postnatal development that have received particular attention are those for language acquisition (mainly nine months to five years), development of emotional control (from birth to two years), motor control (from birth to eight years), and habitual ways of responding, such as enthusiasm and persistence (from six months to two years).

#### Later processes that refine the structure of the brain

The development of the brain does not stop in childhood. As noted above, the formation of new synapses continues throughout life. In the cerebral cortex, this is accompanied by the continued growth of dendrites. From birth to adulthood, the mass of the cortex increases five-fold without any new cells forming – an increase almost entirely due to dendrite growth. It has been shown that there is a marked increase in new synapse growth in the frontal lobes during adolescence so that the frontal lobes are not fully mature until about 25 years of age. Another vital process that occurs during childhood and adolescence is that of progressive myelination. Myelin sheaths are laid down during the postnatal years until early adulthood. Myelination increases the speed of transmission of action potentials along axons. This might



provide a mechanism for stabilising connection times while the body enlarges. The distance from the spinal cord to the foot muscles increases from about 300 mm in a baby to about 1000 mm in an adult; if myelination did not occur, it could take thirty times as long for a command to reach the muscles in an adult.

The development of the cerebellum is delayed compared with other parts of the brain. At the time of birth, the cerebellum is extremely small, but during the first six years of life in humans, it grows to the size of an orange. The cerebellum's role is to assist with the coordination of movement, so its development is delayed so that it matches the period when the child is learning new motor skills.

#### Neural plasticity

Neural plasticity refers to the ability of the mature brain to change itself by generating new neurons or by making new connections. The realisation that the brain can continually change itself is quite new; it has led to significant changes in neuroscience thinking. In the past, it was thought that the structure of the mature mammalian brain could not be changed so that someone who suffered a stroke, or some other form of brain injury would be condemned to a permanent loss of function. However, since 1990 it has become evident that the brain can compensate by creating major changes in connections after injury, and many rehabilitation programs have been developed to take advantage of this capacity.

The ability to grow and make new connections is not restricted to injured brains - it also occurs in normal brains asked to cope with large amounts of new information. For example, an MRI study of the brains of final-year medical students found that the grey matter in their parietal cortex and hippocampus increased substantially in the period leading up to their final exams.

A pioneer in the area of neuroplasticity, Mike Merzenich, has promoted the idea that exercising the brain can increase its capacity as a defence against cognitive deterioration in elderly individuals.

#### Questions for repetition

- How many genes are involved in the development of the mammalian brain?
- How long does the maturation of the frontal cortex take?
- In which brain areas does adult neurogenesis take place to any notable extent?
- What are the components of the peripheral nervous system?
- What are the names of the signalling molecules that orient ventrally or dorsally of the neural tube?
- Where are the first four Hox genes expressed?
- What is one of the main reasons for neural tube defects?

## THE SPINAL CORD

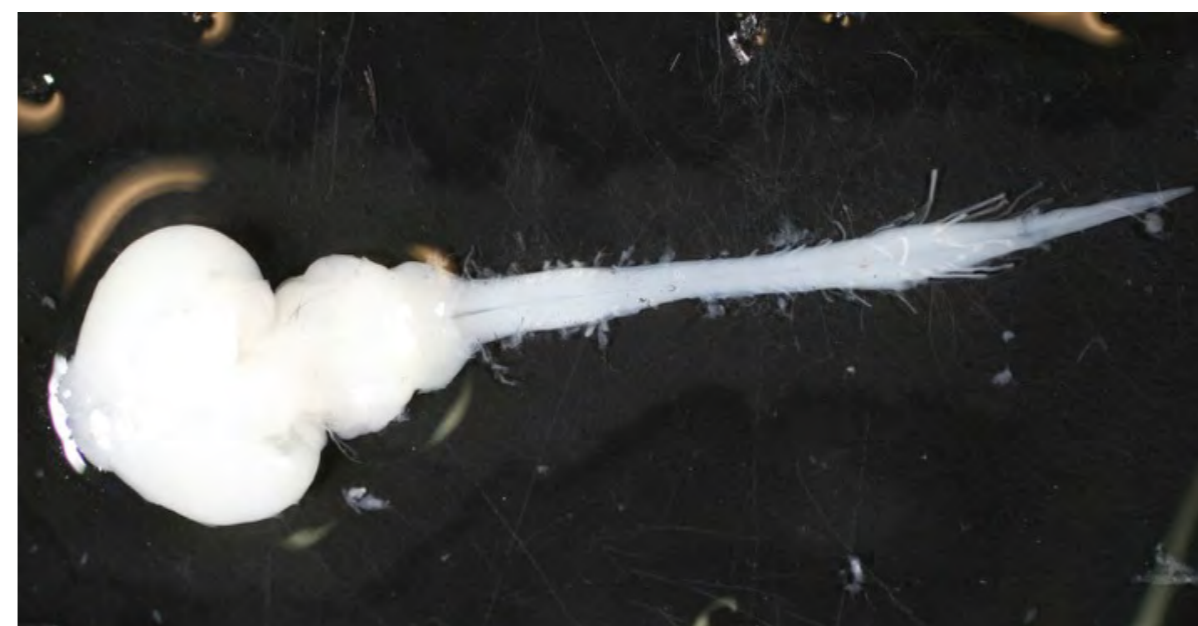### Spinal Cord

The central nervous system consists of the forebrain, brainstem, and spinal cord. The forebrain is comprised of the cerebral hemispheres, olfactory structures, hypothalamus, and diencephalon. The brainstem consists of the midbrain (mesencephalon) and the hindbrain (rhombencephalon), comprising 12 segments.

The spinal cord is the simplest part of the central nervous system containing:

- sensory neurons that receive sensation from the sensory receptors
- motor neurons that control muscles
- long tracts connecting the spinal cord with the brain
- the preganglionic nuclei of the autonomic nervous system
- pattern generators for complex movements such as running at different speeds

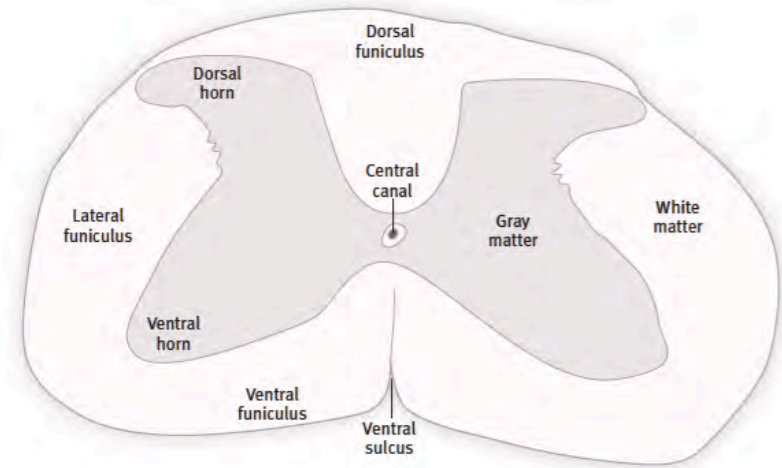
The spinal cord is a long cylindrical structure extending from the base of the skull to the first lumbar vertebra in the human. The spinal cord is noticeably thicker in the regions that are connected to the upper and lower limb.



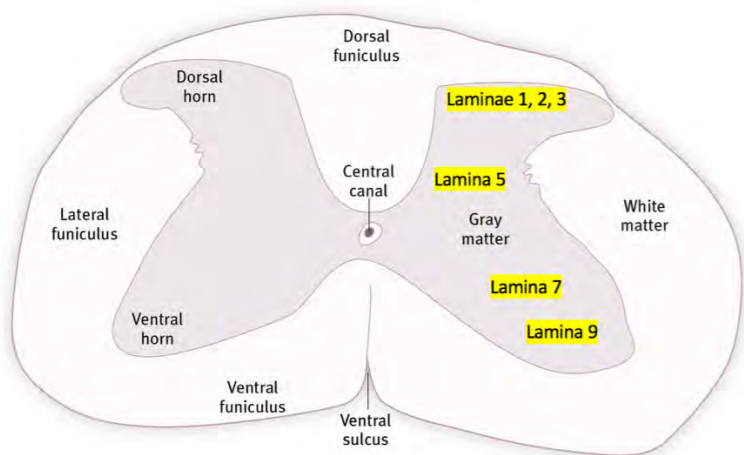
*In this photograph of mouse spinal cord, the thickened regions represent the areas of attachment of the upper and lower limb nerves.*

In a transverse section of the spinal cord, a central butterfly-shaped area of grey matter is surrounded by white matter. The grey matter is divided into ventral and dorsal horns, and the white matter can be divided into three funiculi (columns) – dorsal, lateral and ventral.

The grey matter can be further subdivided into a series of layers called the laminae of Rexed. Layers 1 to 4 form the dorsal horn and are related to sensory input. Layers 7 to 9 form the ventral horn and have functions generally to the motor system, while the limb and trunk motor neurons are located in lamina 9. In between the dorsal and ventral horns lies the lamina 5, which is the site of pattern generators for limb movements. Lamina 6 is small and is not present at all levels.



***Schematic transverse section through the spinal cord.***



***Schematic transverse section through the spinal cord showing important laminae.***

The spinal cord receives sensory information from the skin, joints, and internal organs; this information is processed locally and sent to the brain. The motor neurons in the spinal cord connect with the muscles, blood vessels, and internal organs and can initiate activity in these structures. The brain sends nerve fibre bundles (tracts) to control these motor neurons.

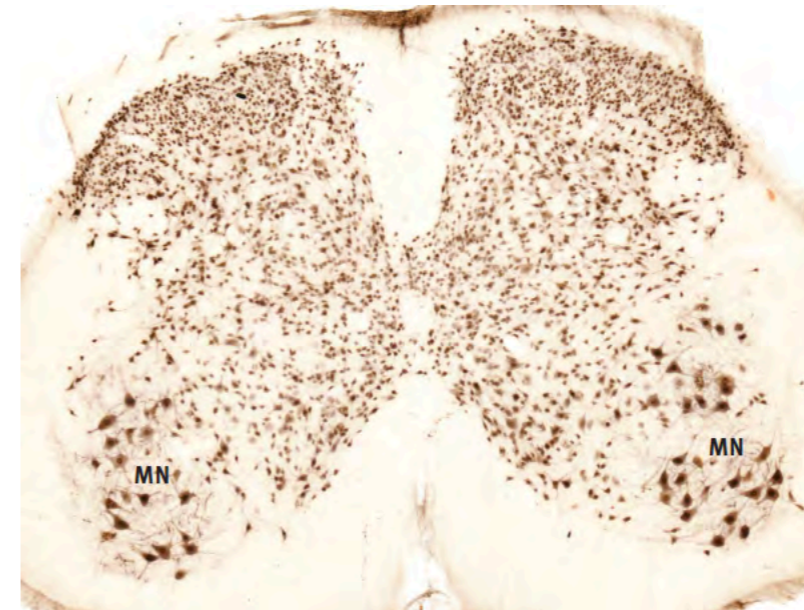
The mammalian spinal cord is made up of six distinct anatomical and functional regions—one for the neck (prebrachial), one for the forelimb (brachial), one for the sympathetic outflow (postbrachial), one for the lower limb (crural), one for the pelvic parasympathetic outflow (postcrural), and a last one for the tail (caudal).

In the human, the prebrachial region extends from spinal cord segments C1 to C4, the brachial region from C5 to T1, the postbrachial region from T2 to L2, the crural region from L3 to S1, the postcrural region from S2 to S4, and the caudal region from S5 to the coccygeal segments. The spinal cord contains sophisticated pattern generators that can initiate different kinds of coordinated movements. Movement patterns generated in the spinal cord include locomotion, posture, and balancing.

### Motor neurons in the spinal cord

Motor neurons initiate muscle fibre contraction and secretion of glands, acting as the final common pathway for motor function's central and peripheral neural pathways. The motor neurons in the spinal cord belong to two major functional groups – somatic and autonomic. Somatic motor neurons innervate skeletal (voluntary) muscle while autonomic motor neurons innervate smooth muscle and glands.

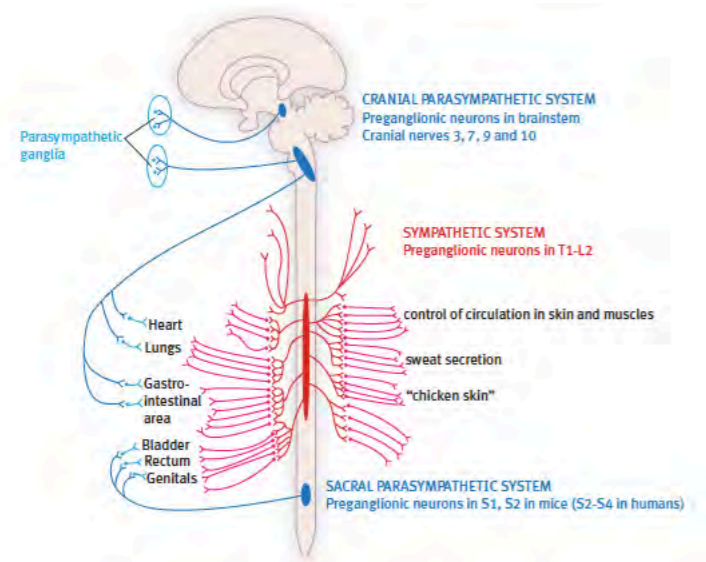
Somatic motor neurons are located in the ventral horn of the grey of the spinal cord in lamina 9. These are large multipolar neurons that stain well with acetylcholinesterase and NeuN markers.



***A transverse section of mammalian spinal cord stained for NeuN showing upper limb motor neurons (MN) in lamina 9 of the ventral horn.***

The lamina 9 motor neurons are large because they each support a very long axon that runs to supply the striated muscles of the axial skeleton (muscles of the neck, trunk, and tail) and the muscles of the upper and lower limbs. The motor neurons innervating axial muscles are present at all spinal cord levels. Still, the large motor neurons innervating limb muscles are only present at the level of origin of the upper limb nerves (C5 to T1 spinal cord segments in the human) and the level of origin of the lower limb nerves (L3 to S1 spinal cord segments in the human).

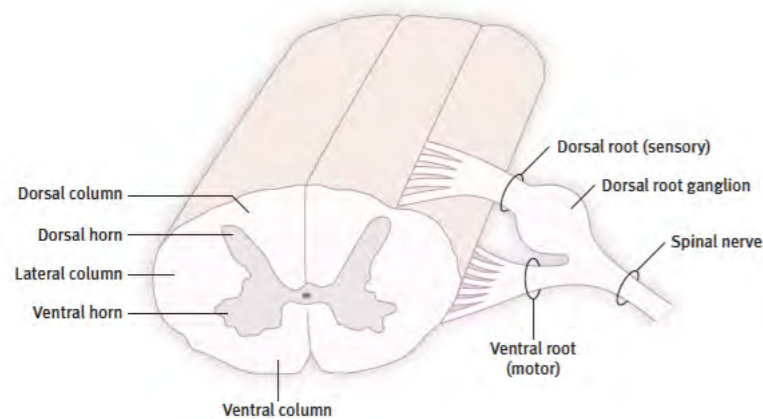
The autonomic motor neurons of the spinal cord can be divided into two separate groups—the preganglionic motor neurons of the sympathetic nervous system and the preganglionic motor neurons of the pelvic parasympathetic system.



**In humans, the sympathetic preganglionic motor neurons are found at the T2 to L2 spinal cord, and the parasympathetic preganglionic motor neurons are located from S2 to S4 spinal cord segments.**

#### Spinal cord nerve roots

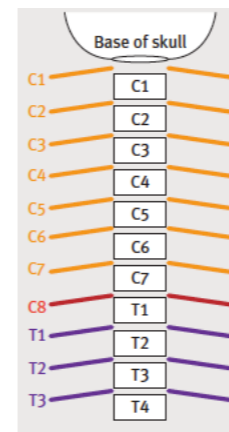
A dorsal and ventral root connects each spinal nerve to the spinal cord. The ventral root contains the axons of motor neurons, and the dorsal root contains sensory axons. The cell bodies of the sensory axons are located in the dorsal root ganglion, which forms a swelling attached to the dorsal root.



#### Overview spinal nerve roots.

#### The spinal nerves

The spinal nerves are named for the vertebra adjacent to their exit, but the naming convention changes from cervical to thoracic and lower levels. In the cervical region, the nerves are named for the vertebral body below their exit so that C1 exits above the C1 vertebra, C2 above the C2 vertebra, and so on. However, in the thoracic and lower vertebral levels, the emerging nerves are named for the vertebral body above their level of exit so that T1 exits below the T1 vertebra, T2 below the T2 vertebra, and so on. This creates a problem for the nerve identity emerging between the C7 vertebra and the T1 vertebra since it does not fit either of these definitions. The solution was to name this nerve the C8 nerve, even though there is no C8 vertebra. The result is that the human has 7 cervical vertebrae and 8 cervical spinal nerves.



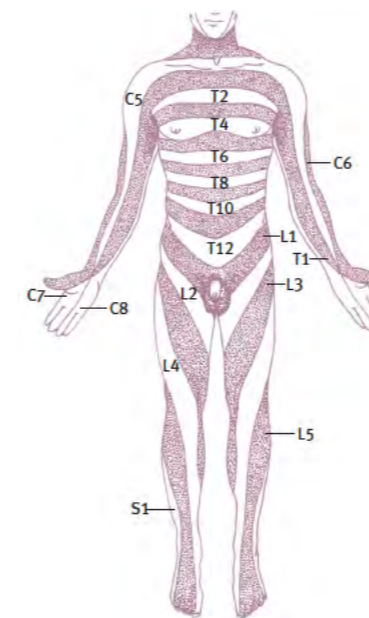
#### Schematic overview of the spinal nerves.

Below the cervical region, there are 12 thoracic vertebrae and 12 thoracic spinal nerves, 5 lumbar vertebrae and 5 lumbar spinal nerves, 5 sacral vertebrae and 5 sacral spinal nerves. The number of tail (coccygeal) vertebrae varies from one to two.

The forelimb muscles are supplied by nerves from the brachial plexus, formed by the C5, C6, C7, C8, and T1 spinal nerves. The hindlimb muscles are supplied by the lumbosacral plexus, formed by the L2, L3, L4, L5, and S1 spinal nerves.

#### Dermatomes

Each spinal nerve supplies a specific strip of skin from the middle of the back to the ventral midline. The skin area provided by a single spinal nerve is called a dermatome. This diagram shows the distribution of the spinal dermatomes from C5 to S1.

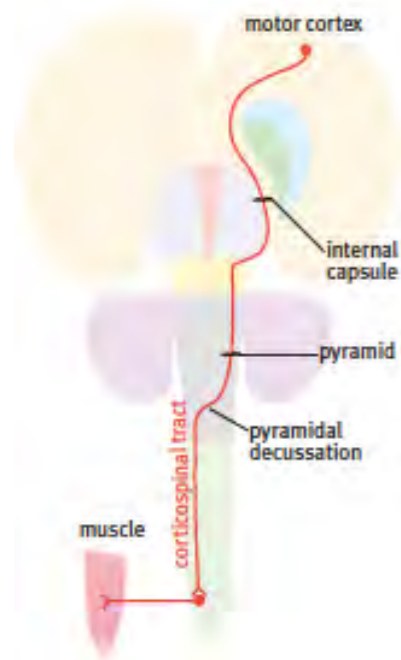


#### The dermatomes of the human body.

## Spinal cord tracts

### *Descending tracts in the spinal cord*

Descending tracts arise in the cerebral cortex and the brainstem. Most descending tracts cross in the brainstem and then descend in either the lateral or ventral funiculus of the spinal cord. The descending tracts terminate on interneurons in laminae 5, 6, and 7, motor neurons in lamina 9, or both. In functional terms, a useful distinction can be made between the descending tracts in the lateral funiculus and those in the ventral funiculus: the lateral funiculus tracts (corticospinal, rubrospinal, lateral reticulospinal) are more concerned with the control of flexor movements and particularly movements of the distal parts of the limbs, whereas the descending tracts of the ventral funiculus (vestibulospinal, tectospinal, medial reticulospinal) are more concerned with the control of extensor (postural) muscles of the trunk and proximal parts of the limbs. The corticospinal tract travels from the motor cortex through the internal capsule, pons, and pyramid to reach the pyramidal decussation, crossing to the opposite side.



### *Schematic overview of the corticospinal tract.*

The internal capsule strip of white matter in the cerebral hemisphere is a common site of damage to the corticospinal tract in humans, where a haemorrhage or blood clot can cause a stroke. An internal capsule stroke results in paralysis and stiffness in the muscles of the opposite side of the body.

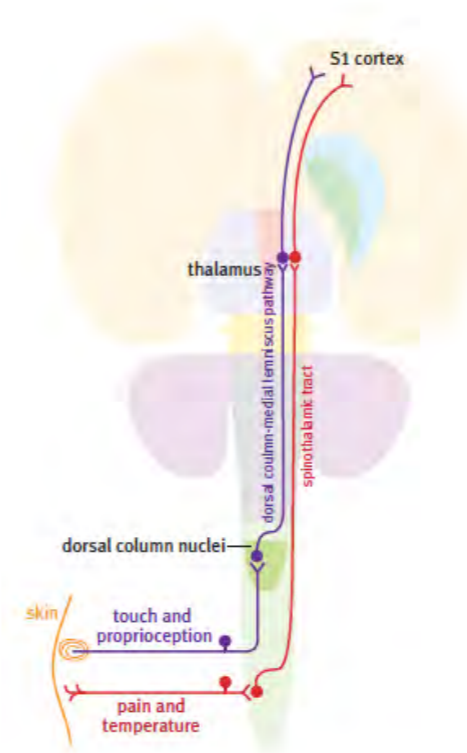
In primates, some corticospinal fibres make direct contact with motor neurons in lamina 9. Still, direct connections from the cerebral cortex to motor neurons are rare or absent in non-primate mammals. The cortical control of limb movements in non-primate mammals is mainly based on a major projection to lamina 5 in the spinal cord, which contains a highly organized system of limb movement pattern generators (Levine et al., 2014).

Some brain stem centres send tracts to the spinal cord. These are the red nucleus (rubrospinal tract), superior colliculus (tectospinal tract), vestibular nuclei (vestibulospinal tracts), and reticular nuclei (reticulospinal tracts).

### *Ascending tracts in the spinal cord*

Both the spinothalamic tracts and the dorsal columns (gracile and cuneate fasciculi) convey somatosensory information from one side of the body to the cerebral cortex of the opposite side via the thalamus. Each of these systems is basically a chain of three neurons: the first

neuron is a dorsal root ganglion cell with its central process entering the spinal cord to ascend for some distance before it synapses with the second neurone in the chain; the axon of the second neuron crosses the midline immediately and climbs to the thalamus; the third neuron sends its axon from the thalamus to the cerebral cortex.



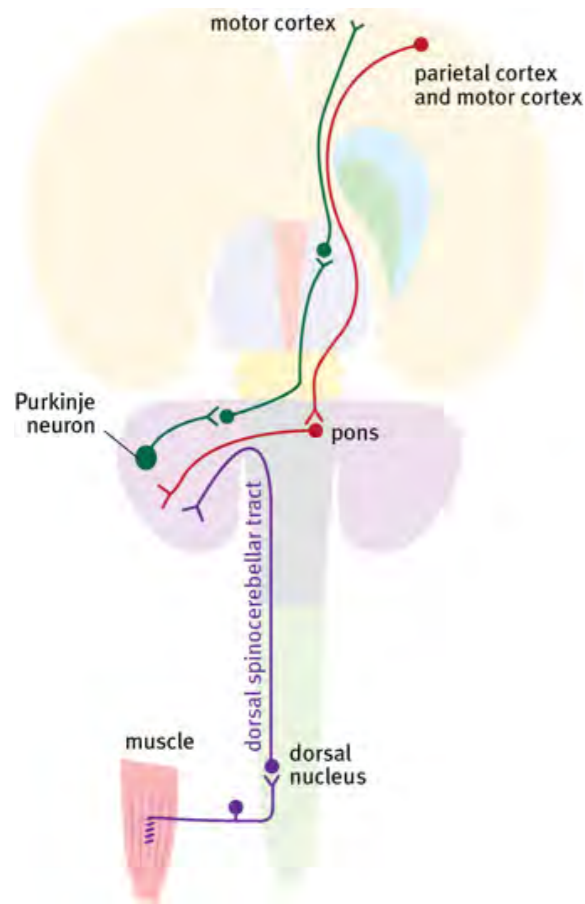
### *Schematic overview of sensory pathways.*

It is important to note that the central process of the first neuron in the spinothalamic system is short (its axon ascends for only a few spinal cord segments). However, the main process of the first neuron of the dorsal column system ascends all the way to the medulla oblongata. The first neuron of the spinothalamic system ascends in the dorsolateral fasciculus (just external to lamina 1), and the cell body of the second neuron may lie in lamina 1, 2, 3, or 4. The axon of the second spinothalamic neuron crosses the midline in the anterior white commissure of the spinal cord. It then ascends in either the lateral spinothalamic pathway (pain and temperature sensation) or the anterior spinothalamic tract (touch sensation). The dorsal column tracts carry touch, deep pressure, proprioceptive, and vibration sense information in the gracile and cuneate fasciculi - the gracile fasciculus mainly conveys information from the hindlimb, and the cuneate fasciculus conveys information from the forelimb. Note that these two pathways do not cross the midline until they reach the brainstem.

### *The spinocerebellar tracts*

The dorsal spinocerebellar and ventral spinocerebellar tracts convey position sense (proprioception) and tactile information to the cerebellum. These tracts end on the same side as they began. As with the other ascending fibre systems, the first neuron of the dorsal spinocerebellar and ventral spinocerebellar systems is a dorsal root ganglion cell. In the case of the dorsal spinocerebellar system, the first neuron ends by synapsing on neurons of the dorsal nucleus (the nucleus of Clarke), which is a prominent cell group found in thoracic and upper lumbar levels (note that these are the same levels at which the preganglionic column of the sympathetic nervous system is located). The dorsal nucleus lies just dorsolateral to the central canal. The axons of these cells form the dorsal spinocerebellar tract in the lateral funiculus and end in the cerebellar cortex of the same side. The ventral spinocerebellar system is more compli-

cated anatomically, but, in general, it is similar to the dorsal spinocerebellar system since it ends in the cerebellum of the same side. Both the dorsal spinocerebellar and ventral spinocerebellar systems serve only the body's rear half; the body's front half is served by an additional spinocerebellar system called the external cuneate system.



**Schematic overview of the spinocerebellar tracts.**

#### Questions for repetition

- Which laminae of the spinal cord are mainly associated with motor functions?
- Which brain area is frequently affected by strokes? What are the consequences?
- Which neurons constitute the spinal cord?
- What sensory information is transmitted in the dorsal columns of the spinal cord?
- From which spinal cord segments do the preganglionic sympathetic nerves originate?

## THE BRAIN STEM

### Brain stem

The brain stem is made up of two parts, the midbrain (mesencephalon) and the hindbrain (rhombencephalon). The midbrain is continuous with the forebrain, and the hindbrain is continuous with the spinal cord.

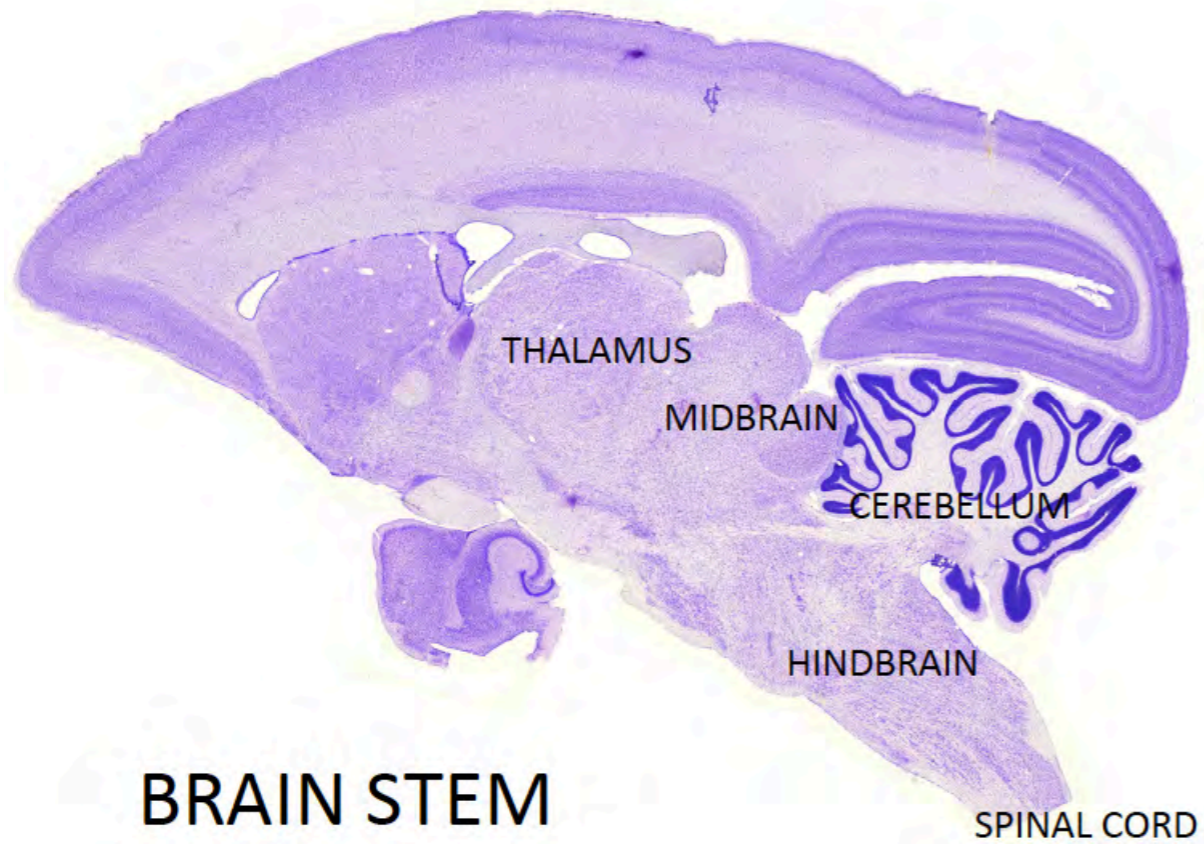
In older textbooks, the brain stem is divided into three parts: midbrain, pons, and medulla oblongata. Unfortunately, this schema, based on a now outdated view of human brain anatomy, is misleading and inaccurate. The confusion relates to the mushroom-like expansion of the pons in the human brain so that it appears to begin adjacent to the midbrain and extend to half the length of the hindbrain. The true nature of the mammalian pons is explained in the Chapter on brain segmentation. In the meantime, we strongly recommend that you use the terms 'midbrain' and 'hindbrain' to subdivide the brain stem.

The brain stem serves a number of key functions:

- the control of the muscles of the eye, face, mouth, and throat; control of the salivary and lacrimal glands;
- control of the internal organs of the thorax and abdomen;
- receiving sensation from the face, mouth, and throat, including taste;
- receiving sensation from the special sense organs for vision, hearing and balance;
- coordination of movement of the limbs and trunk
- centers for control of breathing, micturition, and defecation;
- centers for maintenance of alertness;
- acting as a corridor for long motor and sensory pathways that connect the brain with the spinal cord;
- and as a place of origin of descending motor pathways.

The brain stem is connected with the muscles and sensory organs of the head through ten pairs of cranial nerves (cranial nerves 3 to 12). There is a separate chapter detailing the anatomy and connections of the brain stem cranial nerves.

The brain stem has a basic cylindrical structure, but there are major outgrowths from the dorsal surface. In the midbrain, these dorsal outgrowths are called the superior and inferior colliculi—two pairs of rounded bumps that are receiving centers for visual pathways (the superior colliculi) and auditory pathways (the inferior colliculi). The large outgrowth from the hindbrain is the cerebellum. During early development, the cerebellum grows out of the rostral part of the hindbrain, just caudal to the midbrain.



*A sagittal section through the brain of a marmoset monkey showing the midbrain and hind-brain. The cerebellum is a large outgrowth connected to the dorsal surface of the hind-brain. The two rounded structures on the dorsal surface of the midbrain are the superior and inferior colliculi.*

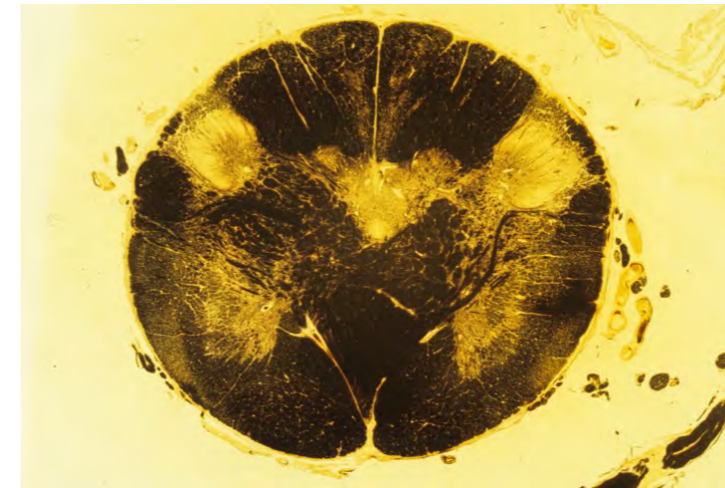
#### BRAIN STEM SECTIONS STAINED FOR MYELIN

The next section involves the examination of images of human brain stem and the identification of major structures in these sections. We will first look at the main features of brain stem sections in summary and then look at details within each section. The sections shown here are stained to show myelinated fibers in order to present a clear picture of the main pathways in the brain stem. Groups of neurons (nuclei) do not stain and appear as pale areas in these sections.

#### SECTIONS THROUGH THE CAUDAL HINDBRAIN

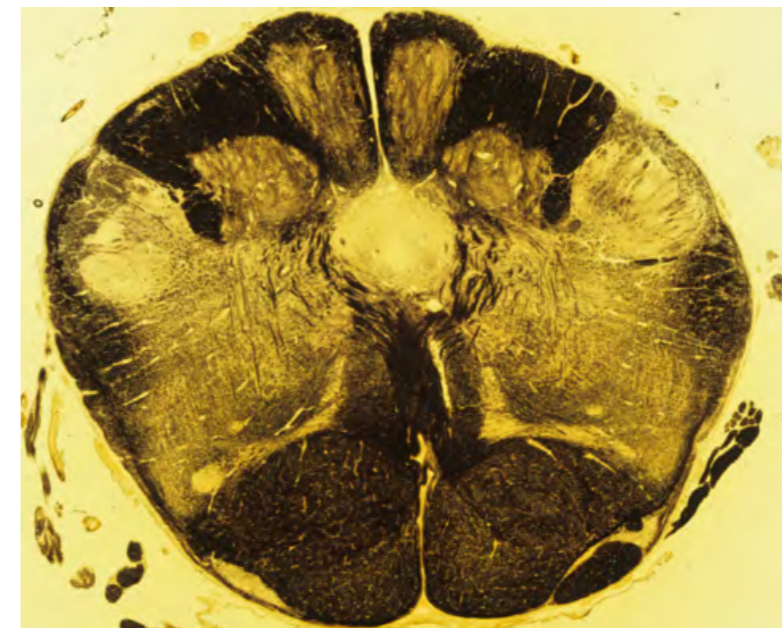
The caudal end of the human brain stem is basically similar to sections of the cervical spinal cord. However, a series of important tract relocations changes the appearance as we ascend through the hindbrain. The main changes are the following:

-The relocation of the corticospinal tract from its lateral position in the spinal cord to a ventral position in the pyramid of the opposite side. The corticospinal tract is a descending tract, but here we are following it in reverse.



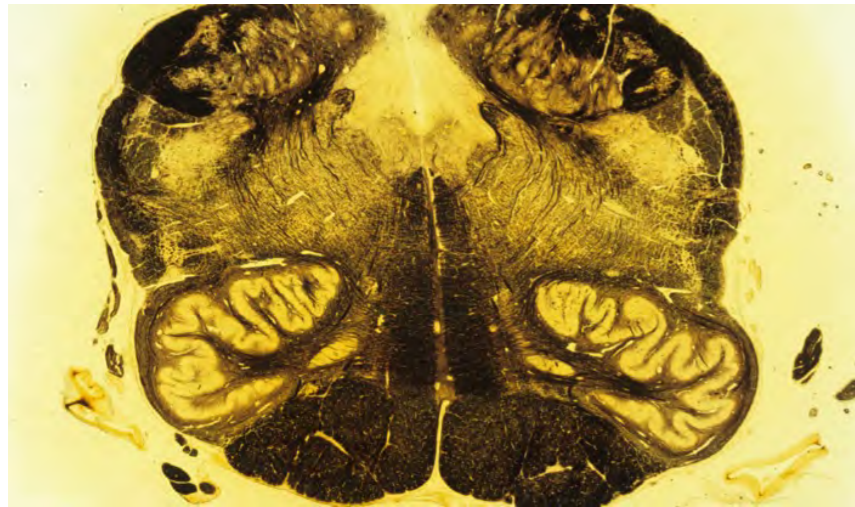
*Caudal human hindbrain at the level of the pyramidal decussation.*

-The termination of the gracile and cuneate fasciculi in the gracile and cuneate nuclei – after synapsing, this pathway continues by crossing the midline (internal arcuate fibers) to reach a position dorsal to the pyramid - the newly formed crossed tract is called the medial lemniscus. The medial lemniscus travels rostrally to reach the thalamus.



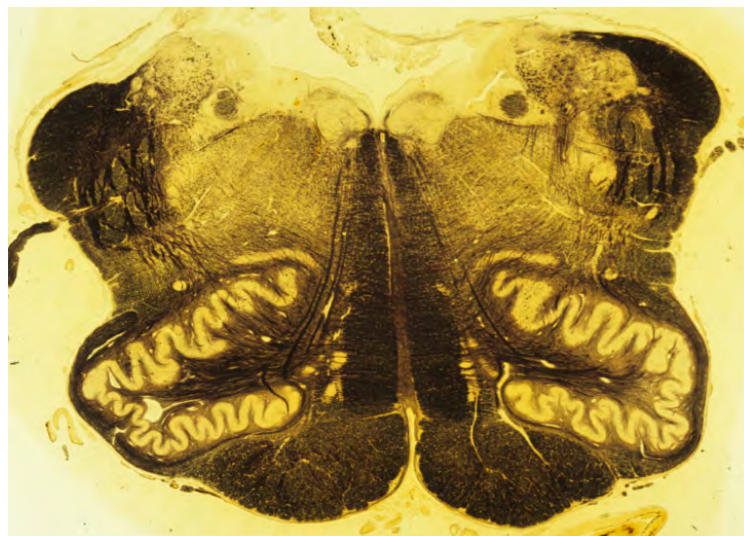
*Hindbrain at the level of the gracile and cuneate nuclei and the somatosensory decussation.*

-After all, the gracile and cuneate fibers have synapsed, and the second axon has crossed the midline to reach the medial lemniscus, the dorsal region of the brain stem is progressively vacated until nothing is left – the remaining space is occupied by the fourth ventricle.



*The hindbrain at the level of the caudal end of the fourth ventricle. The most outstanding feature here is the inferior olive.*

-The caudal end of the fourth ventricle is only a thin tube that is continuous with the central canal, but it expands in more rostral sections to cover the whole dorsal surface of the hindbrain.

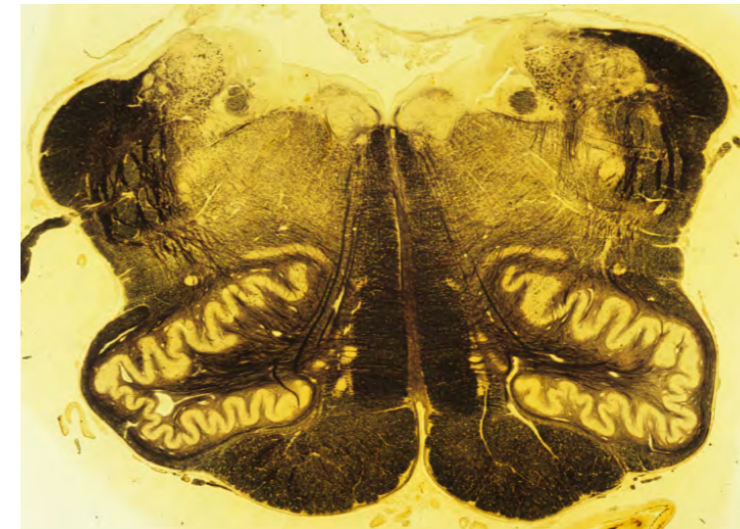


*The hindbrain at the level of the middle of the fourth ventricle.*

#### THE PRECEREBELLAR NUCLEI AND THE CEREBELLAR PEDUNCLES


The rostral hindbrain gives rise to the cerebellum, which expands to cover most of the dorsal surface of the hindbrain. Three large nuclei in the hindbrain project to the cerebellum. They are the external cuneate nucleus, the inferior olive, and the basilar pontine nuclei, and are collectively referred to as precerebellar nuclei. The fibers travelling from the inferior olive and

the pontine nuclei cross the midline to reach the cerebellum. Because the pontine nuclei are huge, this crossing forms a massive outgrowth on the ventral surface of the hindbrain. The fibers travelling from the hindbrain to the cerebellum form two thick bundles called the inferior and middle cerebellar peduncles. The inferior cerebellar peduncle contains the crossed olivocerebellar fibers.



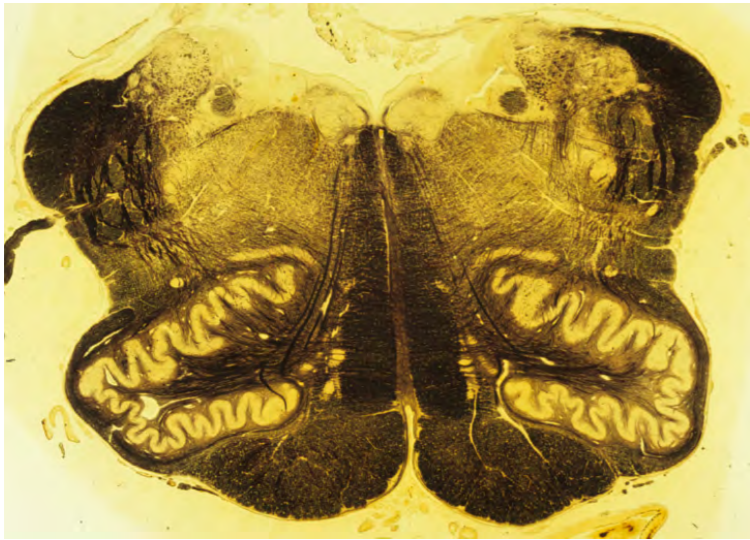
*Hindbrain at the level of the rostral part of the inferior olive.*

The rostral hindbrain contains the basilar pontine nuclei. The axons from these nuclei cross the midline to form the huge middle cerebellar peduncle.



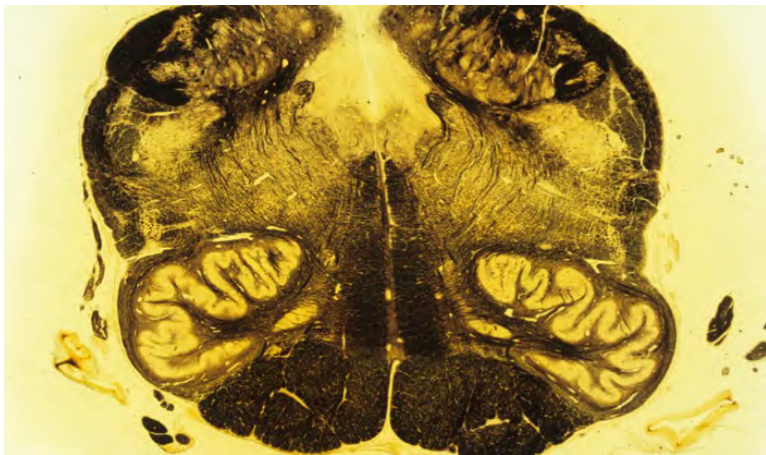
*Rostral hindbrain showing the pontine nuclei and the middle cerebellar peduncles.*

The external cuneate nucleus receives position sense information from the upper limb and neck and sends this information to the cerebellum of the same side. The external cuneate nucleus is located medial to the inferior cerebellar peduncle.



***The external cuneate nucleus lies just medial to the dark inferior cerebellar peduncle at the dorsolateral corner of the rostral hindbrain.***

The inferior olive is a large, folded nucleus in the rostral half of the caudal hindbrain.



***The inferior olive forms a distinctive bulge on the ventral surface of the hindbrain, lateral to the pyramid.***

Axons of inferior olive cells travel to the opposite cerebellar hemisphere via the inferior cerebellar peduncle, where they provide timing signals for coordination of movement.

The basilar pontine nuclei constitute the largest group of neurons in the human brain stem. They receive input from the cerebral cortex and send their axons to the opposite cerebellar hemisphere. The fibers leaving the pontine nuclei form the middle cerebellar peduncle. The pontine nuclei and the crossing pontocerebellar fibers form a massive bulge which covers most of the rostral hindbrain, seen in images in the section above.

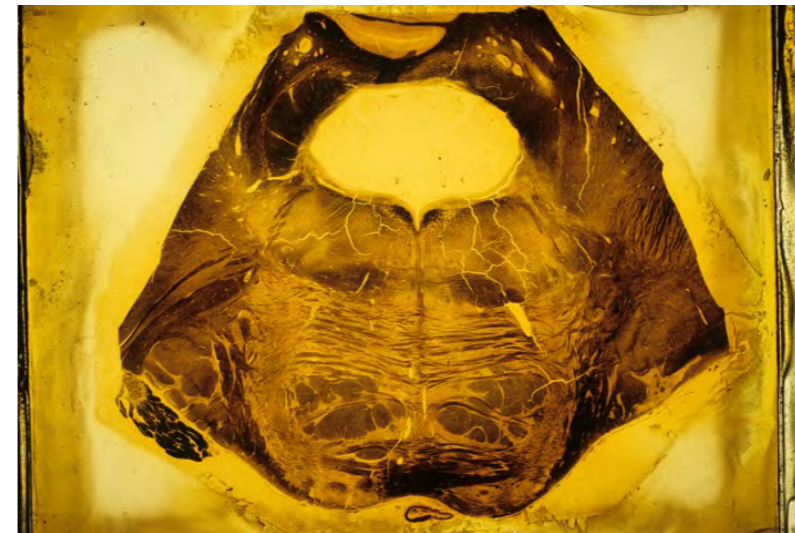#### SECTIONS OF THE ROSTRAL HINDBRAIN SHOWING THE PONTINE EXPANSION

Next, we will examine sections of the rostral hindbrain, where the dominant feature is the pontine expansion. The most useful landmark in identifying the level of these sections is the fourth ventricle. The fourth ventricle is widest at the caudal end of the pontine expansion, and it becomes progressively narrow as it approaches the midbrain, where it forms the tube-like aqueduct.

Cerebrospinal fluid from the ventricles of the forebrain travels down the aqueduct to reach the fourth ventricle. The fluid escapes through holes in the roof of the fourth ventricle to reach the subarachnoid space.

Sections through the pontine expansion look very different from those at the level of the inferior olive because they are dominated by the huge pontine nuclei and crossing pontine fibers. However, some features are continuations of structures observed in the caudal hindbrain.

Examine the following image to identify these features:



-the fibers that form the pyramid are here swallowed up by the pontine nuclei and crossing fibers, but they still form a distinct bundle. However, it is not called the pyramid here; instead, these fibers are referred to as the longitudinal fibers of the pons, which are made up of corticospinal and corticopontine fibers.

-the fibers of the medial lemniscus are still present, but they no longer lie vertically; they are forced to assume a horizontal position, sitting above the pontine expansion.

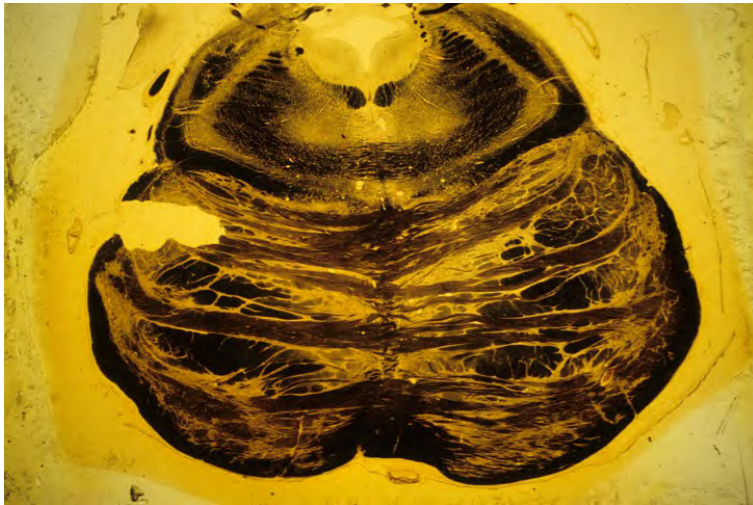
-the fourth ventricle separates the longitudinal part of the hindbrain from the cerebellum. The cerebellum forms the roof of the rostral half of the fourth ventricle

-the inferior cerebellar peduncle is still present, but it has moved dorsally to enter the cerebellum, lying lateral to the fourth ventricle.

A dominant feature of this section is the middle cerebellar peduncle, but it has been cut just before it enters the cerebellum. On the left-hand side of this image, you can see the fibers of the trigeminal nerve as they travel through the middle cerebellar peduncle to reach the surface.

The next image shows a section through the rostral end of the pontine expansion. It shows some features that were seen in the lower section but has some other distinctive features.





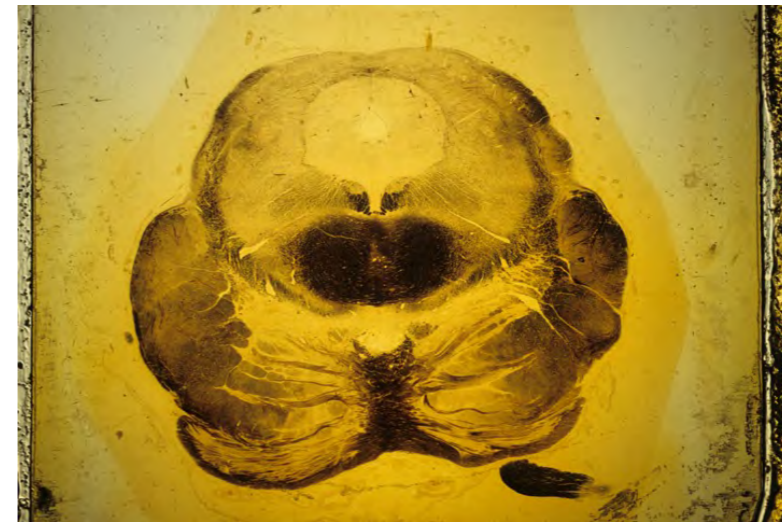
*A section through the rostral hindbrain showing the decussation of the superior cerebellar peduncles.*

- the corticospinal and corticopontine fibers (longitudinal fibers of the pons) form a prominent bundle in the center of the basilar pontine formation
- the medial lemniscus still lies dorsal to the basilar pons, but it has moved away from the midline
- the middle cerebellar peduncle is not seen here because it has left the brain stem to enter the cerebellum
- the fourth ventricle has shrunk down to a small tube that is about to become the aqueduct of the midbrain.

An entirely new feature of this section is the appearance of the superior cerebellar peduncle, which is a very prominent fiber group just dorsal to the medial lemniscus -. This peduncle consists of fibers that have left the cerebellum and are heading toward their termination in the thalamus. At this level, the superior cerebellar peduncle is crossing the midline – the crossing is therefore called the decussation of the superior cerebellar peduncle. This crossing is an important landmark because it occurs in the most rostral segment of the hindbrain (the isthmus).

#### SECTIONS THROUGH THE MIDBRAIN

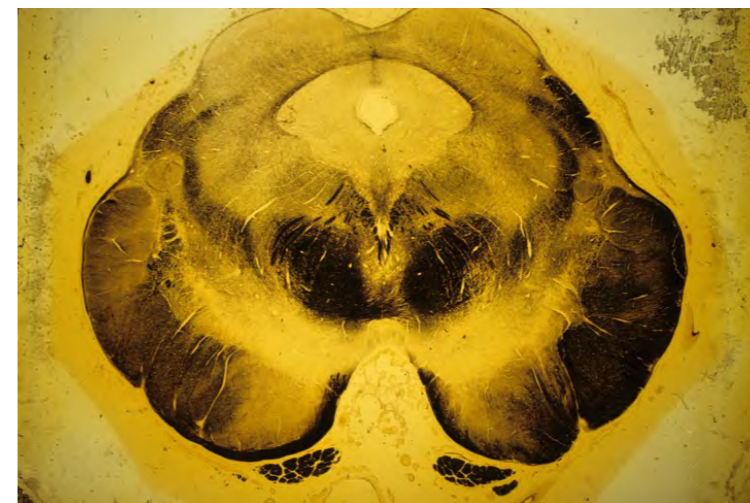
The next image is a section through the caudal midbrain. It is particularly interesting because this part of the midbrain overlaps the isthmus and the rostral part of the basilar pontine formation. The dorsal part of the section is at the caudal part of the inferior colliculus of the midbrain, but the middle of the section shows features of the most rostral segment of the hindbrain – the decussation of the superior cerebellar peduncle and the nucleus of the trochlear nerve.



*A section through the caudal midbrain, showing the overlap with rostral hindbrain structures – the decussation of the superior cerebellar peduncles and the rostral pontine nuclei.*

The most ventral part of the section cuts through the most rostral part of the basilar pontine formation. Lateral to the crossing pontine fibers is a very large fiber bundle formed by the corticospinal and corticopontine fibers. This bundle is called the cerebral peduncle (crus cerebri).

The next section is exclusively a midbrain section at the level of the superior colliculus. In the center is the aqueduct, which is surrounded by the pale periaqueductal gray matter. Above the periaqueductal gray are the two superior colliculi, which have a characteristically laminated appearance.



*A section through the superior colliculus of the midbrain.*

Below the periaqueductal gray are two dark round masses. They contain the fibers of the superior cerebellar peduncle, which is ascending toward the thalamus. However, this region co-

incides with the location of large cells of the red nucleus, a cell group that gives rise to the descending rubrospinal tract. The appearance of the cells is obscured by the fibers of the superior cerebellar peduncle.

Lateral to the red nucleus, at the lateral edge of the midbrain, is the very large cerebral peduncle, which contains corticospinal and corticopontine fibers that are heading towards the hindbrain. On the inner margin of the dark cerebral peduncle is an extensive pale area called the substantia nigra. The reason for the apparently contradictory name is that in fresh brain specimens, the area is stained black by iron deposits. Some of the cells of the substantia nigra contain dopamine, and which project to motor centers in the forebrain.

Between the red nucleus (superior cerebellar peduncle) and the cerebral peduncle is the elongated medial lemniscus, which has been pushed laterally.

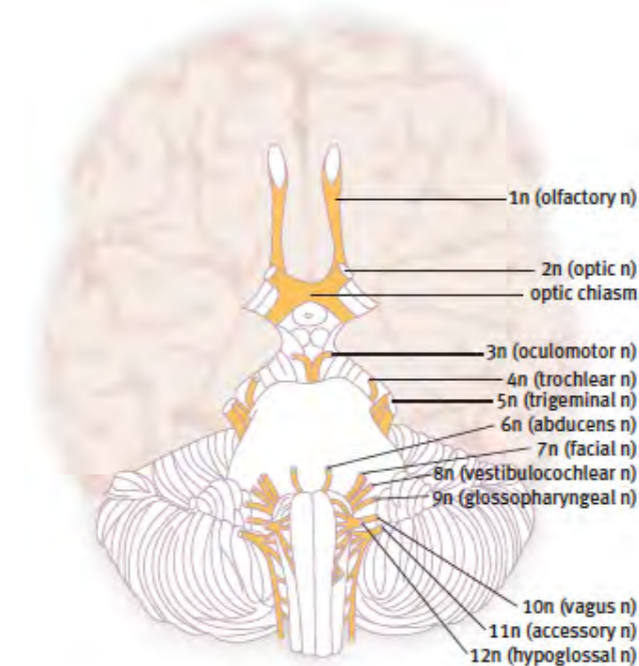
An important feature of this section is the presence of streaks of fibers that start from under the periaqueductal gray and which course through the red nucleus. These are fibers of the oculomotor nerve, which are heading to their point of emergence between the two cerebral peduncles (this space is called the interpeduncular fossa).

#### Questions for repetition

- What is the difference between the spinal cord and the caudal end of the hindbrain?
- In which sensory pathways are the superior and inferior colliculi involved?
- What are the names of the three large nuclei that project from the hindbrain into the cerebellum?
- What is the name of the part of the hindbrain that is most rostrally located?

#### The brain stem cranial nerves

Cranial nerves 1 and 2 (the olfactory and optic nerves) are connected with the forebrain. The remaining ten cranial nerves (cranial nerves 3 to 12) arise from the brain stem.



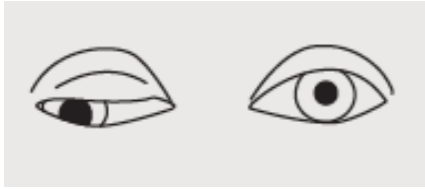
#### *The ventral surface of the human brain showing the origins of the cranial nerves.*

The oculomotor nerve (3n) emerges out of the interpeduncular fossa from the ventral surface of the midbrain. The trochlear nerve (4n) winds around the cerebral peduncle after exiting the dorsal surface of the isthmus (the most rostral segment of the hindbrain). The trigeminal nerve emerges from the basilar pons. The trigeminal nerve (5n) is made up of two parts, a large sensory root, and a smaller motor root. The abducens nerve (6n) emerges from the caudal border of the pons. The facial nerve (7n) and the vestibulocochlear nerve (8n) leave the hindbrain from the lateral part of the trapezoid body. The rootlets of the glossopharyngeal nerve (9n), vagus nerve (10n), and accessory nerve (11n) form a line at the lateral margin of the caudal hindbrain. The rootlets of the hypoglossal nerve emerge from the lateral border of the pyramid.

#### Cranial nerve 3 – the oculomotor nerve

The paired oculomotor nuclei are found at the level of the superior colliculus, close to the midline, and ventral to the periaqueductal grey matter.

The fibers of the oculomotor nerve course through the red nucleus on their way to the interpeduncular fossa. The main oculomotor nucleus contains somatic motor neurons that supply all the eye muscles except the superior oblique and the lateral rectus muscles. The smaller Edinger–Westphal nucleus contains preganglionic parasympathetic neurons that supply the constrictor of the pupil and the ciliary muscle. Damage to the oculomotor nerve results in a divergent squint (the eye on the paralyzed side is pulled laterally and downwards away from the line of vision), drooping of the eyelid (ptosis – due to partial paralysis of the eyelid raising muscle), and dilatation of the pupil.



**Paralysis of the right oculomotor nerve – divergent squint, dilated pupil, and drooping eyelid.**

#### Cranial nerve 4 – the trochlear nerve

The trochlear nucleus is located immediately caudal to the oculomotor complex dorsolateral to the medial longitudinal fasciculus. While the trochlear nucleus was traditionally thought to be located in the midbrain, it is now clear that it belongs to the most rostral segment of the hindbrain, called the isthmus. The small trochlear nerve exits the dorsal surface of the brainstem. It crosses the midline in the superior medullary velum before winding around the cerebral peduncle to supply the superior oblique muscle of the eye.

#### Cranial nerve 5 – the trigeminal nerve

The trigeminal nerve supplies the skin of the face and the muscles of mastication (the chewing muscles). The sensory fibers of the trigeminal nerve connect to a series of large nuclei extending from the rostral hindbrain to the spinal cord. The principal sensory trigeminal nucleus is found at the level where the trigeminal nerve connects with the hindbrain. The trigeminal motor nucleus lies medial to the principal sensory nucleus. The two remaining nuclei of the trigeminal complex are the spinal (descending) and mesencephalic nuclei. The spinal nucleus is found in the dorsolateral hindbrain at all levels below the principal nucleus and is continuous caudally with the substantia gelatinosa of the spinal cord. The mesencephalic nucleus of the trigeminal system is small and difficult to see in low power sections. It consists of a single layer of large round cells on the edge of the periaqueductal gray matter of the midbrain.

#### Cranial nerve 6 – the abducens nerve

The abducens nerve supplies the lateral rectus muscle of the eye. The abducens nucleus lies next to the midline close to the medial longitudinal fasciculus. The fibers of the emerging abducens nerve can be seen running dorsoventrally through the tegmentum of the hindbrain.

#### Cranial nerve 7 – the facial nerve

The facial nerve supplies the muscles of the face. It also supplies taste sensory fibers to the front of the tongue and parasympathetic fibers to the submandibular salivary gland and other small glands in the head. The motor fibers leaving the main facial nucleus take an unusual course through the hindbrain. They travel dorsomedially to curl around the abducens nucleus before heading ventrolaterally to exit the brainstem ventral to the trigeminal sensory nucleus. Taste fibers in the facial nerve connect with the nucleus of the solitary tract.

#### Cranial nerve 8 – the vestibulocochlear nerve

The vestibulocochlear nerve receives sensory fibers from the organs of balance (mainly the semicircular canals) and hearing (the cochlea). In a transverse section of the junction of the pons and medulla, the vestibulocochlear nerve enters the brainstem as two separate bundles, which straddle the inferior cerebellar peduncle. Those entering ventral to the peduncle are the vestibular fibers, while those seen dorsal and lateral to the peduncle are the cochlear fibers. The dorsal and ventral cochlear nuclei are pale areas embedded within the fibers of the cochlear nerve as it arches around the peduncle. The dorsal cochlear nucleus is the more prominent of the two; it is easily recognizable in sections as it surmounts the inferior cerebellar peduncle. Four nuclei comprise the vestibular nuclear complex. They are named superior, lateral, medial, and spinal (descending) vestibular nuclei. These four nuclei are arranged within a diamond-shaped area in the floor of the fourth ventricle.

#### Cranial nerve 9 – the glossopharyngeal nerve

The glossopharyngeal nerve receives taste fibers from the posterior third of the tongue, which terminates in the nucleus of the solitary tract. The glossopharyngeal nerve contains parasympathetic fibers that supply the parotid salivary gland, and which arise in the inferior salivatory nucleus. It also supplies a single pharyngeal muscle, the palatoglossus, with fibers that arise in the nucleus ambiguus.

#### Cranial nerve 10 – the vagus nerve

The vagus nerve supplies parasympathetic fibers to the thoracic and abdominal viscera. The parasympathetic nucleus of the vagus (the dorsal motor nucleus of the vagus) lies just medial to the sulcus limitans in sections of the open medulla. The nucleus of the solitary tract lies just lateral to the dorsal motor nucleus of the vagus. It receives taste fibers from the facial, glossopharyngeal and vagus nerves, and general visceral afferent fibers from the vagus nerve. The nucleus ambiguus contains large multipolar motor neurons, which supply the pharynx, palate, and larynx muscles via the vagus, cranial accessory, and glossopharyngeal nerves.

#### Cranial nerve 11 – the accessory nerve

The cranial part of the accessory nerve arises from the nucleus ambiguus and is considered by many to be just a part of the vagus nerve. It contributes to the vagal supply of the pharynx. The spinal root of the accessory nerve is a motor nerve supplying sternomastoid and trapezius muscles in the neck. It arises from motoneurons in cervical spinal cord levels C2 to C4. It travels into the cranial cavity to join briefly with the vagus nerve before descending into the posterior triangle of the neck.

#### Cranial nerve 12 – the hypoglossal nerve

The hypoglossal nerve supplies the muscles of the tongue. The hypoglossal nucleus lies immediately dorsal to the medial longitudinal fasciculus and is medial to the dorsal motor nucleus of the vagus in the floor of the fourth ventricle. The hypoglossal nerve fibers travel ventrally to emerge between the inferior olive and pyramid.

#### Functional classification of motor and sensory nerve fibers

The fibers that travel in the cranial nerves can be classified on the basis of their functions. Efferent (motor) fibers are classified as either somatic efferent, visceral efferent, or branchial efferent. Afferent (sensory) fibers are classified as somatic sensory, visceral sensory, or special sensory. The following table summarises the functional components of each of the cranial nerves

Number	Name	Functional components	Function
1	Olfactory	Special sensory	Sensation of smell.
2	Optic	Special sensory	Sensation of vision.
3	Oculomotor	Somatic motor	Controls four of the six eye muscles and the eyelid muscle.
		Visceral motor	Parasympathetic control of the lens and pupil.
4	Trochlear	Somatic motor	Controls the superior oblique muscle of the eye.
5	Trigeminal	Somatic sensory	Sensation from the skin of the face.
		Branchial motor	Controls the muscles of the jaw.
6	Abducens	Somatic motor	Controls the lateral rectus muscle of the eye.
7	Facial	Somatic sensory	Taste sensation from the front of the tongue.
		Branchial motor	Controls the muscles of the face.
8	Vestibulocochlear	Special sensory	Sensations of hearing and balance.
9	Glossopharyngeal	Branchial motor	Controls one of the muscles of the pharynx.
		Visceral motor	Parasympathetic control of the parotid salivary gland.
		Special sensory	Taste sensation from the back part of the tongue.
		Visceral sensory	Detection of blood pressure changes.
10	Vagus	Visceral motor	Parasympathetic control of internal organs of the thorax and abdomen.
		Visceral sensory	Sensation from the internal organs.
		Branchial motor	Controls the muscles of the pharynx and larynx.
11	Accessory (spinal part)	Somatic motor	Controls two large neck muscles.
12	Hypoglossal	Somatic motor	Controls the muscles of the tongue.

#### Questions for repetition

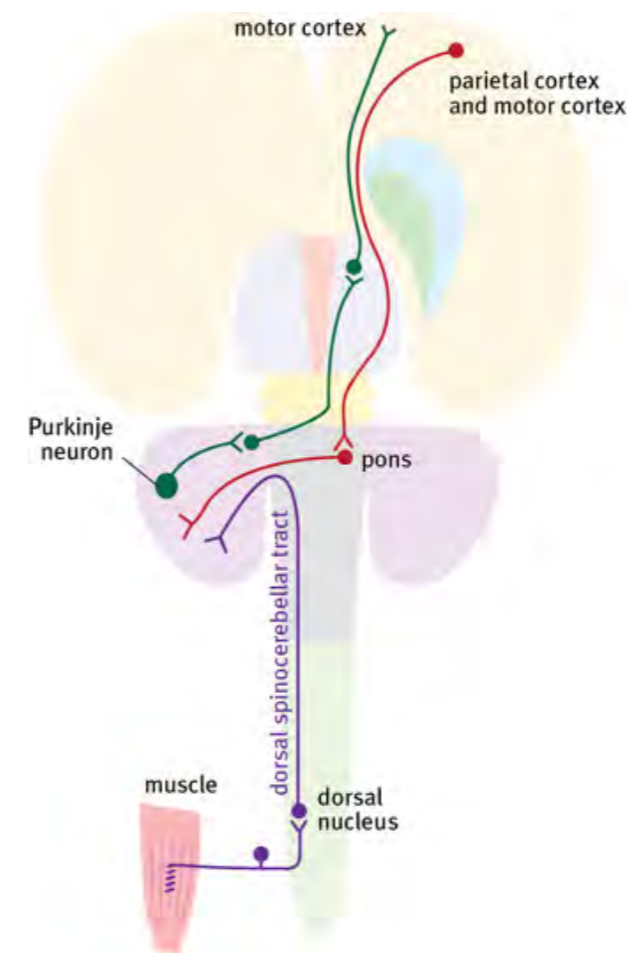
- Which cranial nerves are connected to the brain stem?
- Name the consequences of paralysis of the third cranial nerve.
- What is the fifth cranial nerve also called?
- What is the function of the sixth cranial nerve?
- What do the parasympathetic fibers of the glossopharyngeal nerve innervate?
- How many functional components does the eleventh cranial nerve have?

## The cerebellum

The cerebellum is an outgrowth of the rostral hindbrain, arising from the region just caudal to the midbrain (the isthmus and the first rhombomere). The developing cerebellum is relatively small at birth, but it grows rapidly in the postnatal period.

The central white matter of the cerebellum is arranged like the trunk of a tree, with a series of major branches covered with grey matter. In a mid-sagittal section, the cerebellum looks like a slice of cauliflower, with branches of white matter forming the major lobules of the central part of the cerebellum. The part of the cerebellum in the midline is called the vermis. The vermis consists of ten recognizable lobules in all mammals.

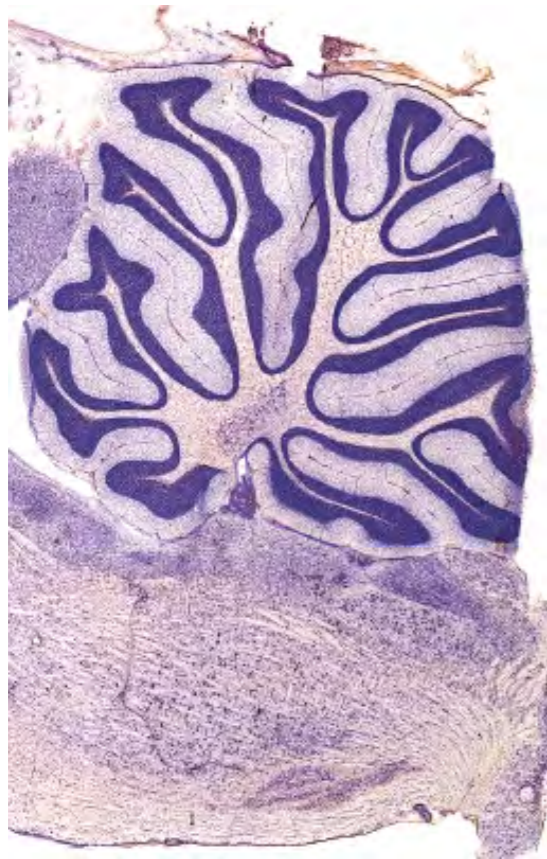
The cerebral cortex relies on the cerebellum for the coordination of movement. The cerebral cortex requests information from the cerebellum via the huge corticopontine pathway that travels to the rostral hindbrain and which synapses in the pontine nuclei. The pontine nuclei send their axons to the opposite side of the cerebellum via the middle cerebellar peduncle. The cerebellum responds to requests from the forebrain via the superior cerebellar peduncle, which travels to the ventrolateral thalamic nucleus of the opposite side. The inferior cerebellar peduncle carries fibers that arise in the spinal cord and brainstem on their way to the cerebellar cortex.



*The dorsal spinocerebellar tract and the pathways connecting the cerebellum, thalamus, motor cortex, and pons.*

### Lobules of the cerebellar vermis and the cerebellar hemisphere

The vermis of the cerebellum in all mammals is divided into ten lobules by a series of deep fissures. The largest of these fissures is the primary fissure, which divides the anterior vermis (lobules 1-5) from the posterior vermis (lobules 6-10). Each of the lobules has a traditional Latin name, but the only one worth remembering is the nodule, which is the name for lobule 10. The human cerebellar hemisphere is extraordinarily elaborate, marked by hundreds of individual folia that run from medial to lateral.

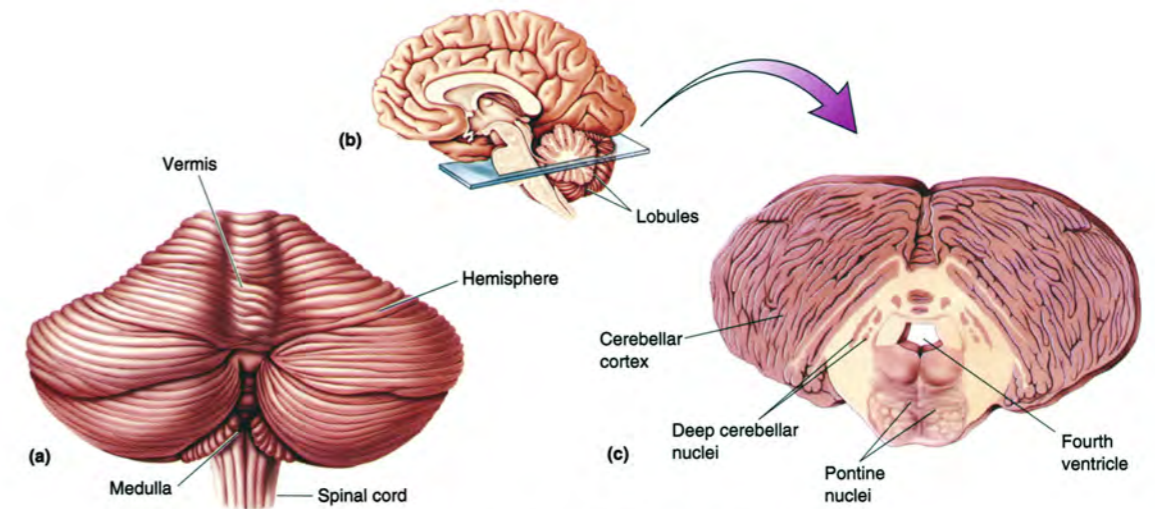


*A sagittal section of rat cerebellum showing the ten lobules of the vermis. The deep primary fissure separates lobules 1-5 (on the left) from lobules 6-10 (on the right).*

The center of the cerebellum is filled with fibers – called the deep cerebellar white matter. Embedded in the white matter are three deep cerebellar nuclei on each side. The largest of these nuclei is the dentate nucleus, which is laterally placed.

### Cerebellar peduncles

The cerebellum is connected to the hindbrain by three cerebellar peduncles on each side: the inferior peduncle mainly contains fibers entering the cerebellum from the spinal cord and the inferior olive; the huge middle peduncle contains fiber projecting from the basilar pons to the cerebellum; the superior peduncle contains fibers that leave the cerebellum to travel through the red nucleus to reach the thalamus.



Bear et al., Neuroscience, Exploring the Brain, 2nd ed., Lippincott, 2001.

*A diagram of the human cerebellum showing the vermis and the hemispheres (a) and the deep cerebellar nuclei (c).*

### The cerebellum has an ipsilateral connection with the body

Each side of the cerebral cortex is connected to sensory and motor activities on the opposite side of the body, but each side of the cerebellum is connected to the same side of the body. When one cerebellar hemisphere is damaged, the classic symptoms of cerebellar damage, which are incoordination of voluntary movement and tremor, occur on the same side as the damage.

### The role of the cerebellum in motor control

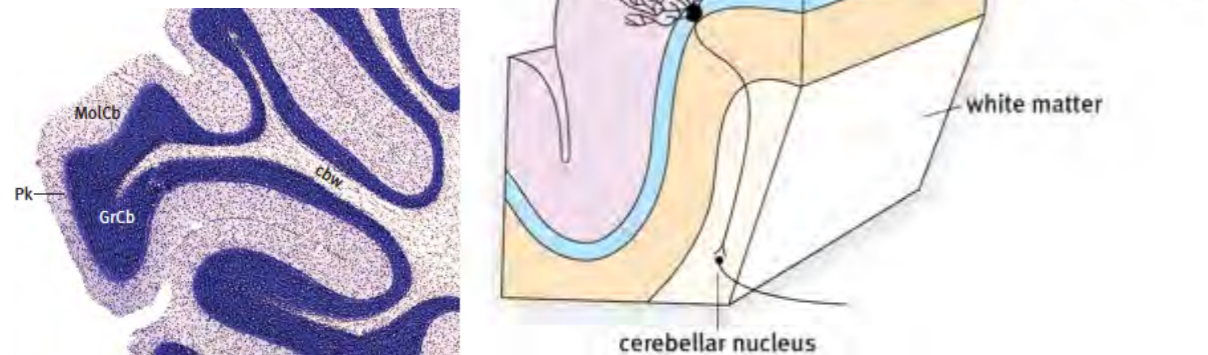
The cerebellum is responsible for the coordination of complex movements. It does this by comparing the motor commands with the actual body movements that result. On the basis of this comparison, it can adjust motor control to improve accuracy. This monitoring and feedback occur in real-time and is most important at the crucial end stages of a purposeful movement. The cerebellum plays a vital role in the management of posture and balance; it receives input from the vestibular system so that it can monitor the position of the body in space, and it can make major postural adjustments if the person is in danger of losing their balance. In primates, the cerebellum is vital for coordinating the movements of the hands and eyes. For monkeys, life in the trees depends entirely on the ability to plan and execute acrobatic leaps involving the cerebellum, vestibular system, eyes, and hands. Humans have the most sophisticated version of binocular vision among the primates and have long fingers and opposable thumbs. The human cerebellum has evolved to capitalize on these capacities through the precise coordination of skilled finger movements. The fine coordination of finger movement under the control of binocular vision has given humans access to tool manufacture.

### The histological structure of the cerebellar cortex

The cerebellar cortex is made up of three layers, the outer molecular layer, the Purkinje cell layer, and the inner granule cell layer. Deep to the granule cell layer is the deep cerebellar white matter.

The structure of the cerebellar cortex is extraordinarily uniform; the same three layers are seen in all parts of the cerebellum, and their relative thickness does not vary. Deep to the cortex is the deep cerebellar white matter.

The large Purkinje cells are the output cells of the cerebellar cortex. Their axons project to the cerebellar nuclei.



**Cerebellar cortex.** The Nissl stained section above shows the molecular layer (MoCb), the Purkinje cell layer (Pk), the granule cell layer (GrCb), and the deep cerebellar white matter (cbw). The diagram below shows the dendritic tree of a Purkinje cell in the molecular layer and the termination of the Purkinje cell axon in a deep cerebellar nucleus.

### Mossy fibers and climbing fibers

Most of the fibers projecting to the cerebellar cortex are mossy fibers that synapse with granule cells. The exception is the input from the inferior olive, which goes directly to the dendritic trees of the Purkinje cells in the form of climbing fibers. The mossy fibers arise from cells in the pontine nuclei and other large precerebellar nuclei in the hindbrain and from the spinal cord. The granule cells send their axons to the dendrites of Purkinje cells. The granule cells are tiny but very tightly packed - about one million per cubic millimeter; the granule cells comprise about 70 % of all the neurons in the brain. As noted above, the axons from the inferior olivary nucleus form climbing fibers, which make direct contact with the dendritic trees of the Purkinje cells. There is evidence that the inferior olivary cells control the time code of the cerebellum, thus ensuring that every learned movement is played back in exactly the right timing sequence—the inferior olive cells fire at about 10 Hz (ten action potentials per second).

Microelectrode recordings in the rat suggest that every folium in the cerebellum codes a different movement sequence. For example, some are concerned with taking food with the fingers and transferring it to the mouth, and others are involved in running behavior. Given the tens of thousands of folia in the human cerebellum, it is possible that the cerebellum keeps learning new movement sequences into adult life. Perhaps there is even a backhand folium in keen tennis players!

The largest connection of the human cerebellum is the connection with the motor cortex. The huge corticopontine pathway arises from the cerebral cortex, synapses in the pons, and enters the cerebellum through the middle cerebellar peduncle. This seems to be a way for the motor cortex to ask for help from the cerebellum when coordination of a complex movement is required. The answer comes back to the motor cortex via the superior cerebellar peduncle. The fibers of the superior cerebellar peduncle synapse in the ventrolateral nucleus of the thalamus, and the thalamocortical fibers travel to the motor cortex.

The relationship between cell numbers in the cerebral cortex and the cerebellum is very consistent across the mammalian groups. Although the size of the cerebral cortex varies a great deal from one mammalian family to another, the proportional relationship between the number of cerebral cortical cells and the number of cerebellar cells is the same—about 1:4.

The main way the cerebellum tracks movement in the limbs is from sensations from the skin. It used to be thought that the most important information on movement would come from

joint receptors and muscle stretch receptors, but it now appears that most of the input comes from receptors that detect sensations of stretching, contact, or folding in the skin. These sensations provide very fine detail on the movement of the limbs and other body parts.

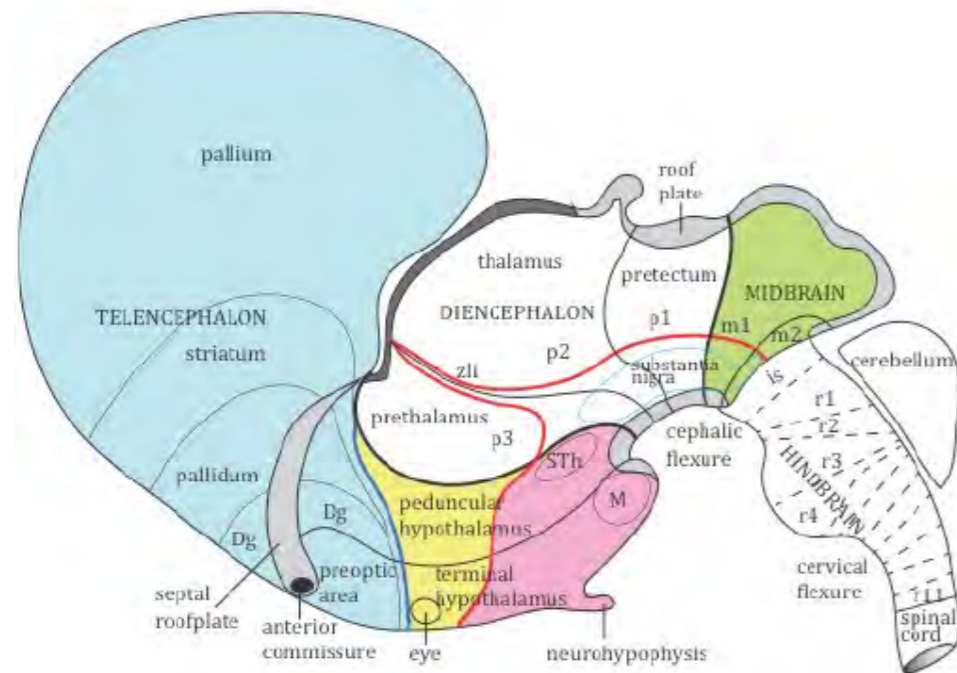
### Questions for repetition

- Of how many layers is the cortex of the cerebellum constituted?
- Is the cerebellum also connected "side-wise inverted" with the muscles of the other half of the body?
- To which cells do the granule cells send their axon potentials?
- How can the cerebellum coordinate the correct timing of movement signals?
- What are classic symptoms of damage to the cerebellum?

## DIENCEPHALON

### The diencephalon

The diencephalon sits between the midbrain and the hypothalamus. The central part of the diencephalon is the thalamus. The other parts of the diencephalon are the prethalamus in front of the thalamus and the pretectal area behind. Each of the three parts of the diencephalon is a complete segment of the neural tube, with alar and basal components, called the diencephalic prosomeres: the pretectal area is included in diencephalic prosomere 1; the thalamic area is included in diencephalic prosomere 2; the prethalamus is included in diencephalic prosomere 3. The word ‘diencephalon’ means ‘interbrain’—referring to the fact that this region links the main parts of the forebrain with the brainstem.



*A diagram showing the segmental components of the developing brain. The diencephalic segments p1, p2, and p3 are shown. Note the habenular stalk at the caudal end of the dorsal surface of the thalamus.*

### Thalamus

In a mid-sagittal section of the brain, the thalamus sits dorsal to the hypothalamus. This led to a long-held misunderstanding that the hypothalamus is actually ventral to the thalamus in topological terms. However, the relationship between the two is not as it seems. Because of the sharp (almost 180 degrees) bending of the neuraxis at the midbrain during development (the cephalic flexure), the hypothalamus is **actually rostral** to the diencephalon in developmental terms.

The thalamus receives input from all the sensory systems except the olfactory system. Each of the visual, auditory, and touch (somatosensory) sensory pathways terminates in its own special part of the thalamus: the visual pathway ends in the dorsal lateral geniculate nucleus; the auditory pathway ends in the medial geniculate nucleus; the touch pathway ends in the ventroposterior nucleus. Each of these sensory thalamic nuclei then sends sensory information to the cortical area reserved for that modality. In addition, information on movement coordination from the cerebellum also reaches the ventrolateral nucleus of the thalamus, and the information is sent on to the part of the cortex concerned with motor control – the primary motor cortex.

It is not necessary to memorize the names of all the thalamic nuclei; the key ones are the nuclei that connect to the main sensory pathways—ventroposterior (VP, somatosensory), dorsal lateral geniculate (DLG, vision), and medial geniculate (MG, hearing), to which should be added the ventrolateral nucleus (VL), which receives input from the cerebellum and globus pallidus and projects to the motor cortex. The remaining thalamic nuclei project to association areas of the cerebral cortex.

The dorsomedial edge of the thalamus carries the habenular nuclei, to which are attached the stalk of the pineal gland. The pineal gland secretes melatonin, which influences the sleep cycle.

### Prethalamus

The most rostral diencephalic prosomere (p3) contains the zona incerta – an important region for motor control. In Parkinson’s disease, stimulating electrodes that are inserted into the zona incerta can minimize tremors and muscle stiffness in patients with Parkinsonism. This is called deep brain stimulation (DBS), and the treatment is usually very successful. The reticular nuclei of p3 play an important role during sleep by controlling the output of the thalamus to the cortex. After sleep is established, the inhibitory (GABAergic) neurons of p3 take control of the activity of the main thalamic nuclei to set up a rhythmic wave pattern of electrical activity in the cortex.

### Pretectal area

The most caudal diencephalic prosomere (p1) contains the nuclei of the pretectal area. These nuclei play a role in visual reflexes. A prominent p1 landmark at the junction of the prethalamus with the midbrain is the posterior commissure, which belongs to p1 and not to the midbrain, as previously supposed.

### Questions for repetition

- Of what parts does the diencephalon consist of?
- Describe the spatial relationship of the thalamus and hypothalamus from a developmental perspective?
- Which thalamic nucleus is integrated into the visual pathway?
- Which part of the diencephalon is stimulated with deep brain stimulation to combat Parkinsonism?
- In which function is the pretectal area involved?

## HYPOTHALAMUS

### The hypothalamus

The name 'hypothalamus' is derived from an outdated view that the hypothalamus was simply a ventral addition to the thalamus. New data from developmental gene expression has revealed a far more critical role for the hypothalamus. It is now clear that the hypothalamus is formed from the most rostral part of the neural tube, and it is responsible for generating the whole of the telencephalon from its alar plate. It is by far the most crucial center in the developing human brain.

One of the reasons for misunderstanding the proper anatomical place of the hypothalamus is a lack of appreciation of the effect of the cervical flexure of the developing neural tube. This severe bend in the embryonic neuraxis pushes the hypothalamus to its adult position under the thalamus.

The hypothalamus comprises the first two neural segments – the terminal prosomere and the peduncular prosomere. The terminal hypothalamic prosomere gives rise to the eye and the telencephalon from its alar plate, giving rise to the posterior pituitary gland from its basal plate. The peduncular hypothalamic prosomere is connected to prosomere 3 of the diencephalon

### Features of the hypothalamus seen in a mid-sagittal section

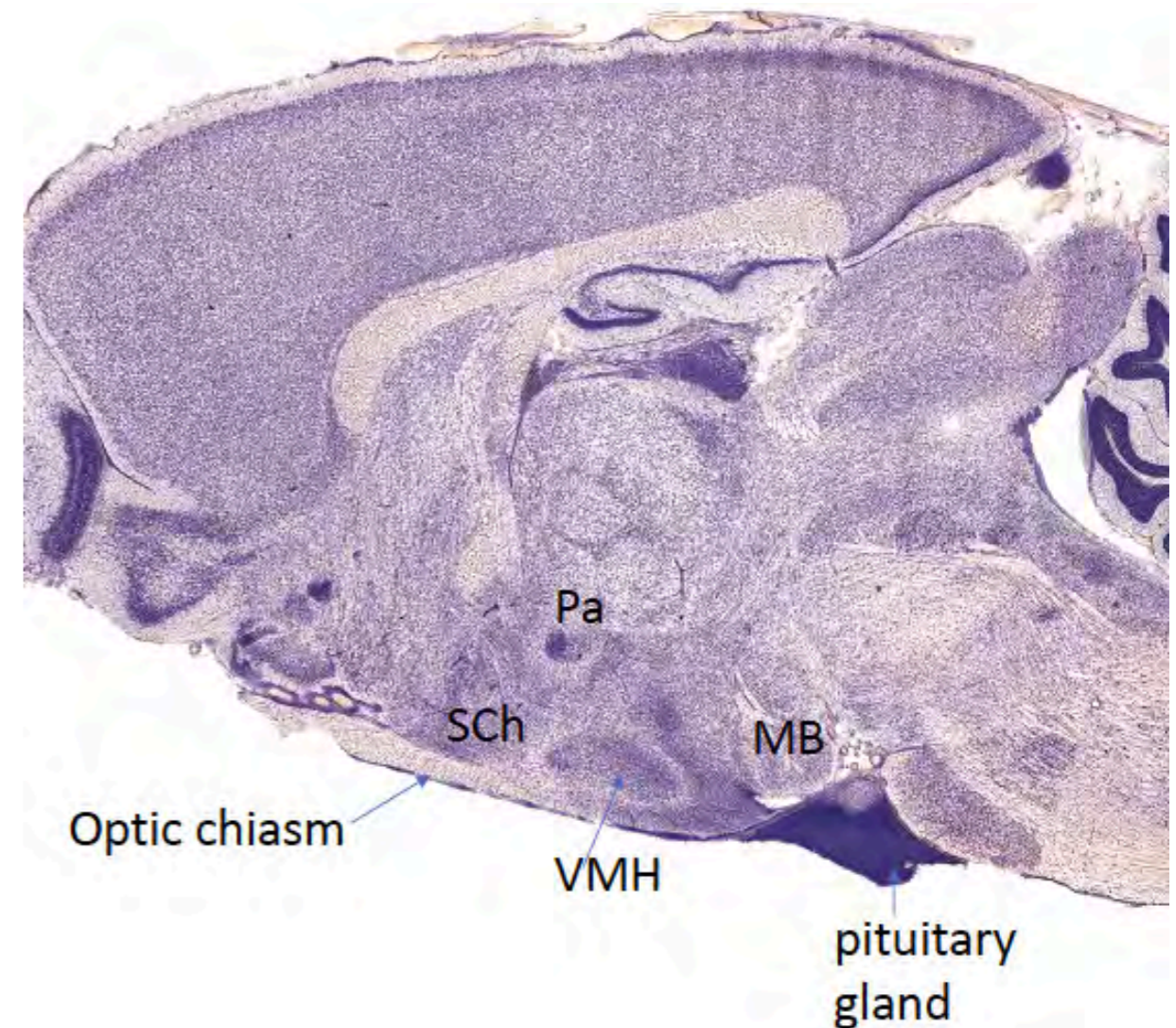
In a mid-sagittal section of the brain, the prominent anatomical landmarks of the hypothalamus can be seen – the optic chiasm rostrally, the mammillary bodies caudally, and the pituitary stalk between the two.

The most rostral part of the hypothalamus sits above the optic chiasm. The hypothalamic nucleus sitting immediately above the chiasm is appropriately called the suprachiasmatic nucleus. This nucleus serves as a 24-hour clock for the brain; its neurons have an internal timing system that can be adjusted with light intensity information from the optic nerves. If an animal is kept in complete darkness, the clock reverts to a 25-hour cycle. The clock is essential for the timing of peaks of hormonal secretions from endocrine glands.

The central part of the hypothalamus that bears the pituitary stalk is called the tuber cinereum.

### The hypothalamus and survival behaviors

During vertebrate evolution, complex behaviors and movement sets became organized in a hierarchy of modules in the brain. At the top of the hierarchy are behaviors relating to the survival of the individual and the species. These include eating, drinking, defensive behaviors, reproduction, and the basic movement patterns needed to explore the immediate environment. These survival behaviors are primarily controlled by the hypothalamus. The hypothalamic control centers for survival behaviors are clustered in two main groups. The first group includes systems for defense, reproduction, and ingestion (feeding and drinking). The nuclei that control these behavior sets, including the large ventromedial nucleus, are located in the medial half of the hypothalamus. Each specific behavior set, such as eating, is related to one particular set of hypothalamic nuclei. The second group of survival behavior organizers is located in the mammillary body in the caudal part of the hypothalamus and in nearby midbrain parts (the substantia nigra and the ventral tegmental area). This second group initiates exploratory and foraging behaviors, such as turning the head and eyes toward an object of interest and walking or running to explore the surroundings.



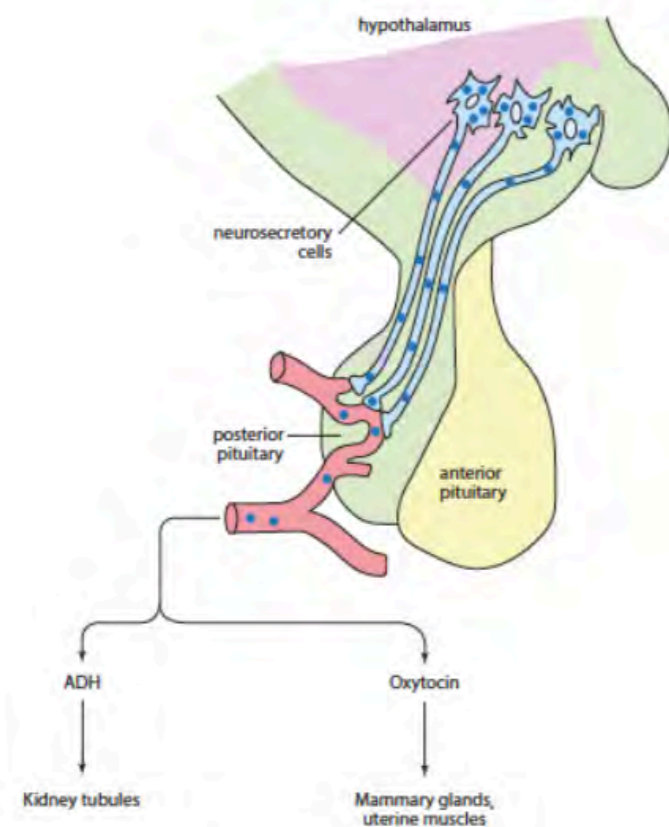
*A sagittal section of the rat brain showing the main parts of the hypothalamus. The pituitary stalk is attached close to VMH. MB=mammillary body; Pa=paraventricular nucleus; SCh=suprachiasmatic nucleus; VMH=ventromedial hypothalamic nucleus.*



### Control of the endocrine system by the hypothalamus

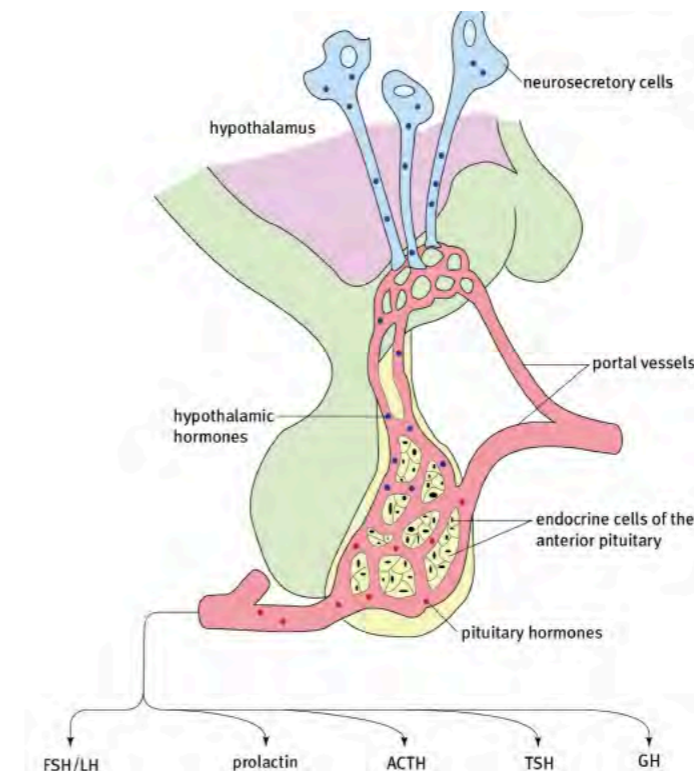
The hypothalamus has several powerful neuron groups that control the hormonal secretions of the pituitary gland. Langdon-Brown famously described the pituitary gland as 'the leader in the endocrine orchestra' (Hubble, 1961). This is a clever metaphor that reserves the role of the conductor of the orchestra for the hypothalamus. In an orchestra, the conductor gives directions to the first violin, who is the orchestra's leader.

Hypothalamic control over the posterior pituitary is direct. Large neurosecretory cells in the paraventricular and supraoptic nuclei send their axons to the posterior pituitary, releasing oxytocin and vasopressin into the bloodstream. Oxytocin stimulates contraction of the uterus at birth and initiates milk secretion after birth. It also plays an important role in adult pair-bonding and maternal-infant attachment. Vasopressin, also called antidiuretic hormone (ADH), increases blood pressure and controls urine production.



**Hypothalamic secretion of the posterior pituitary hormones oxytocin and ADH (vasopressin). The hormones are produced by neurosecretory cells in the paraventricular nucleus and are released from axon terminals that reach the posterior pituitary.**

The control over the anterior pituitary is not as direct: cells in the paraventricular nucleus release tiny amounts of releasing hormones into a specialized portal blood system that carries them to the anterior pituitary. A portal blood system has two sets of capillaries connected by a portal vein. In the case of the pituitary, the first capillary bed collects the releasing hormones from the hypothalamus. Small portal veins transport the releasing hormones to the second capillary bed in the anterior pituitary, where they reach endocrine secreting cells. The releasing hormones stimulate the release of the major hormones from anterior pituitary cells - growth hormone (GH), thyroid-stimulating hormone (TSH), adrenocorticotrophic hormone (ACTH), follicle-stimulating hormone (FSH), prolactin (PRL), and luteinizing hormone (LH).



**The hypothalamus secretes releasing hormones which stimulate the endocrine cells of the anterior pituitary to release their hormone products. The releasing hormones are delivered to hypothalamic capillaries that drain into veins which form a special portal venous system. The portal veins end in a second capillary system in the anterior pituitary.**

### Questions for repetition

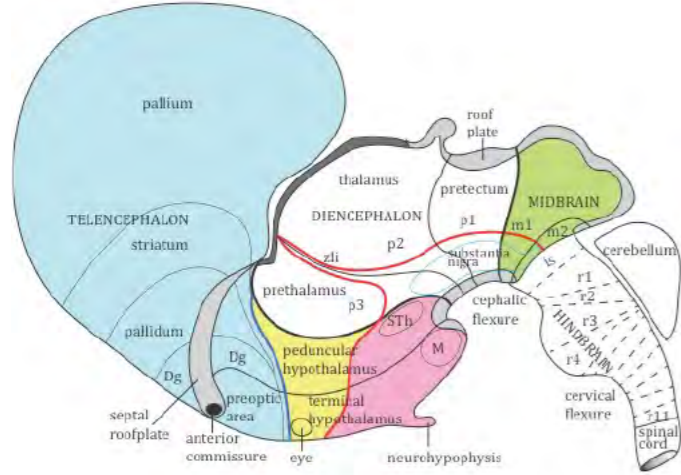
- From which prosomeres does the hypothalamus arise?
- Which hypothalamic nucleus is responsible for determining the circadian rhythm?
- Which hypothalamic structures are involved in behaviors such as foraging and exploration?
- What hormones are secreted in the posterior pituitary gland?
- What kind of hormones are secreted in the anterior pituitary gland?

## Telencephalon

### The Telencephalon

#### TELENCEPHALON – THE CEREBRAL HEMISPHERES

The two telencephalic outgrowths arise from the developing hypothalamus. The telencephalic outgrowth on each side forms the cerebral hemisphere or cerebrum. The cerebral hemisphere of each side consists of an outer layer or pallium and a subpallial layer. The pallium includes the cortex. The subpallium forms several deep cell groups, the largest of which are the striatum and pallidum (sometimes called the basal ganglia).



**The two telencephalic outgrowths arise from the alar plate of the rostral hypothalamic segment. This diagram shows only one telencephalic outgrowth. The telencephalon forms the pallium (the future cortex) and the subpallium (mainly the striatum and pallidum).**

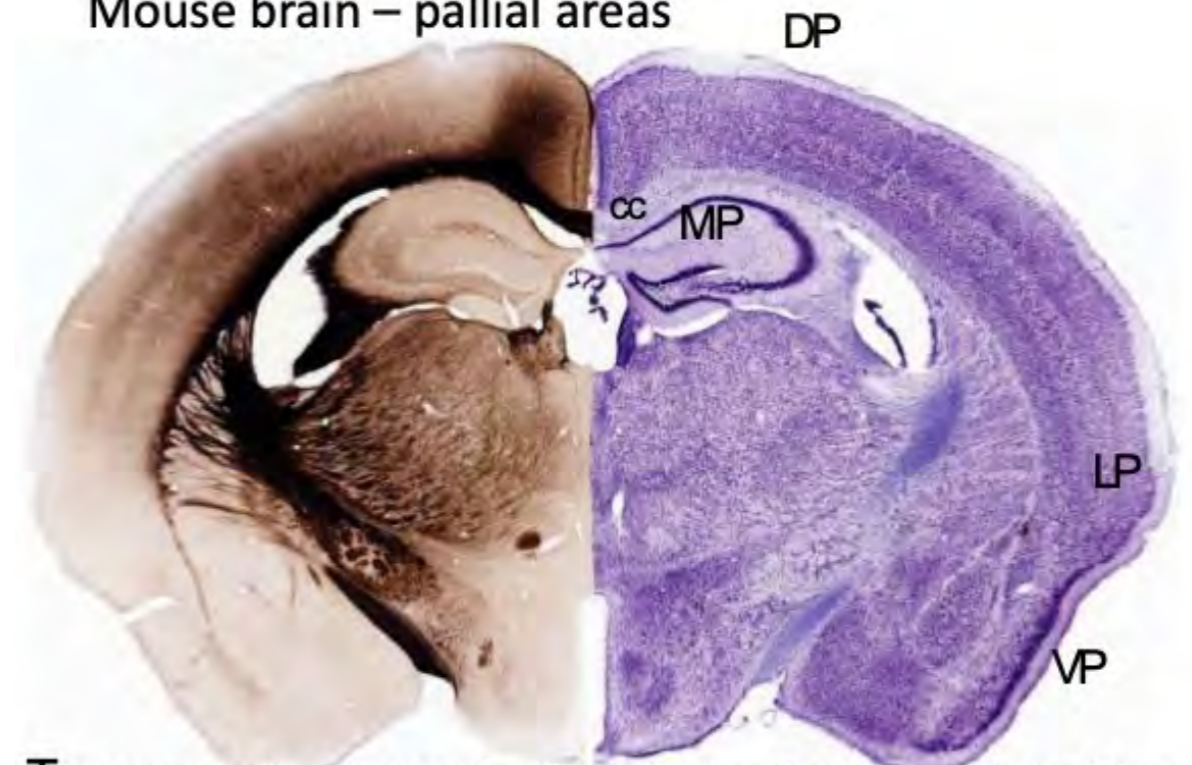
The pallium can be divided into medial, dorsal, lateral, and ventral. In mammals, most of the cerebral cortex is derived from the dorsal pallium and is called the neocortex. The areas deriving from the ventral pallium mainly belong to the olfactory system. The olfactory cortex is sometimes referred to as allocortex.

The smaller lateral pallium, which lies between the neocortex and the olfactory cortical areas, forms a small area of the neocortex called the insula, which is mainly devoted to taste and visceral sensation. The medial pallial subdivision gives rise to the hippocampus.

#### Neocortex

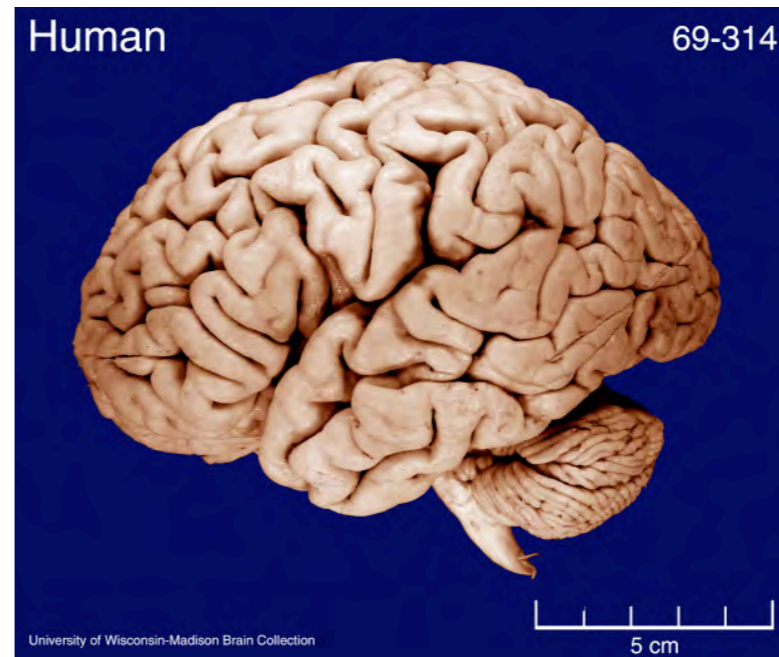
The human neocortex is massively expanded. Folding increases its surface area, forming raised areas (gyri) and grooves (sulci).

### Mouse brain – pallial areas



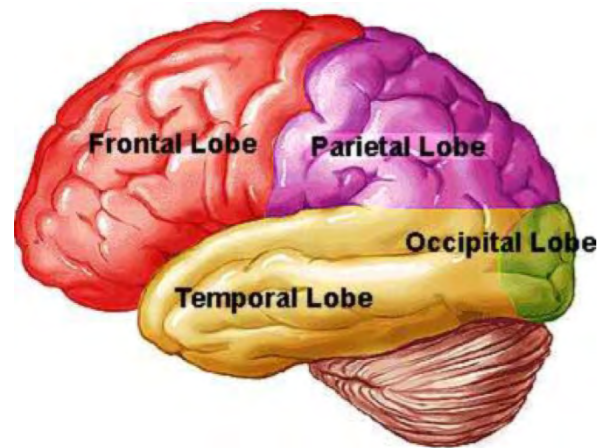
**The corpus callosum separates the medial pallium (hippocampus) from the dorsal pallium (neocortex)**

**A coronal section through the forebrain of a mouse showing the four pallial areas – medial pallium (MP), dorsal pallium (DP), lateral pallium (LP), and ventral pallium (VP). The corpus callosum separates the medial pallium (hippocampus) from the dorsal pallium (neocortex).**



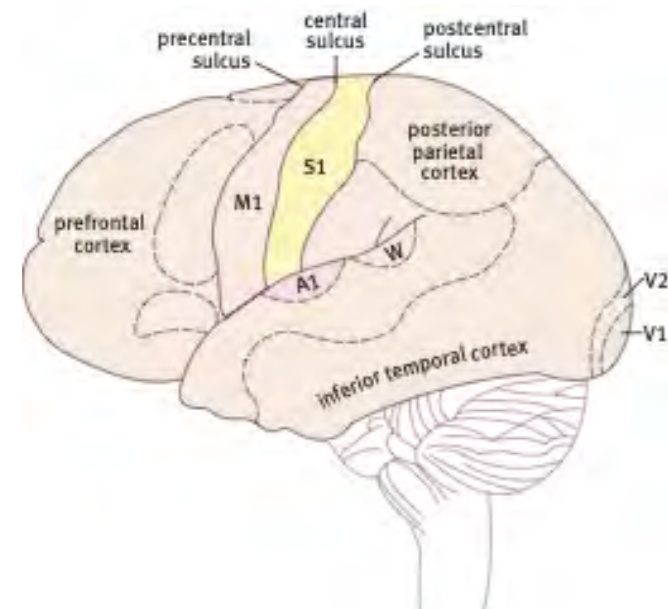
**The pattern of sulci and gyri varies from person to person, but some gyri can be consistently identified.**

The cerebrum can be divided into lobes, which are named for the overlying cranial bones – frontal, parietal, temporal, and occipital.



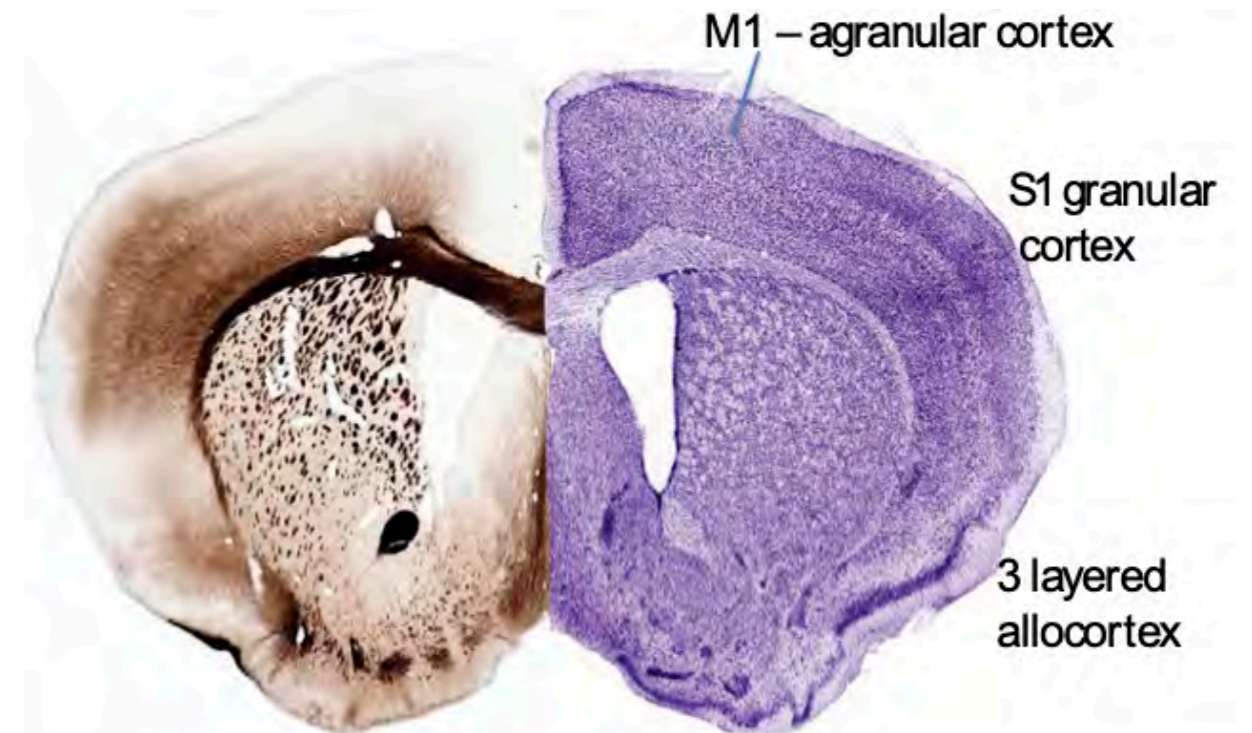
*The lobes of the cerebrum as viewed from the lateral side. The central sulcus separates the frontal and parietal lobes. The lateral fissure separates the temporal lobe from the frontal and parietal lobes.*

The neocortex has well-defined sensory areas for the reception of touch (S1), vision (V1), hearing (A1), and taste. The visual cortex is located in the occipital pole of the cortex, and the auditory cortex is located in the temporal lobe. The touch (somatosensory cortex) is located rostrally near the frontal pole. The neocortex has no olfactory sensory area because all olfactory information projects to the ventral cortical areas – the olfactory bulb, olfactory tubercle, and piriform cortex. In front of the somatosensory cortex is the primary motor cortex – an area devoted to voluntary motor control of the opposite side of the body. Electrical stimulation of the motor cortex produces movements on the opposite side of the body. The motor cortex sends a major pathway to the brainstem (corticobulbar tract) and another to the spinal cord (corticospinal tract) to initiate movements.



*The primary sensory and motor areas in the cortex. The primary somatosensory area (S1) is separated from the primary motor area (M1) by the central sulcus. The primary auditory area is separated from S1 by the deep lateral fissure (not labeled here). The primary visual area is almost entirely located on the medial side of the occipital lobe. The taste area cannot be seen in this diagram because it is hidden in the lateral fissure.*

At a histological level, the neocortex is made up of six well-defined layers, numbered one to six. The primary sensory areas are characterized by dense layers of granule cells - layers 2 and 4. The primary motor cortex is characterized by a prominent pyramidal cell layer (layer 5) and a virtual absence of the main granule cell layer (layer 4) and so is often referred to as the agranular cortex. Many pyramidal cells in layer 5 are very large, sending axons over great distances to reach motor neurons in the spinal cord.



*A coronal section of the mouse forebrain showing the histological difference between the primary motor cortex (M1) and primary somatosensory cortex (S2). The granular layer 4 is missing from M1 but very prominent in S1.*

### The Hippocampus

The hippocampus is the part of the cerebral cortex that is involved in memory systems. The hippocampus arises from the medial pallium. It consists of the dentate gyrus, the three CA regions, the subiculum, and the entorhinal cortex. The hippocampus is responsible for short-term memory registration.

The entorhinal cortex is located in the parahippocampal gyrus is like a GPS that contains a precise two-dimensional grid map of surroundings; it helps to link the memory of events to the place in which they occurred. The entorhinal cortex sends place information to the hippocampus in a chain of connections from the dentate gyrus, the CA3 region, and finally to the CA1 region. The CA1 region sends its information to the subiculum, which is the output center for the hippocampus. The subiculum projects to the septum and hypothalamus via a large fiber bundle called the fornix.

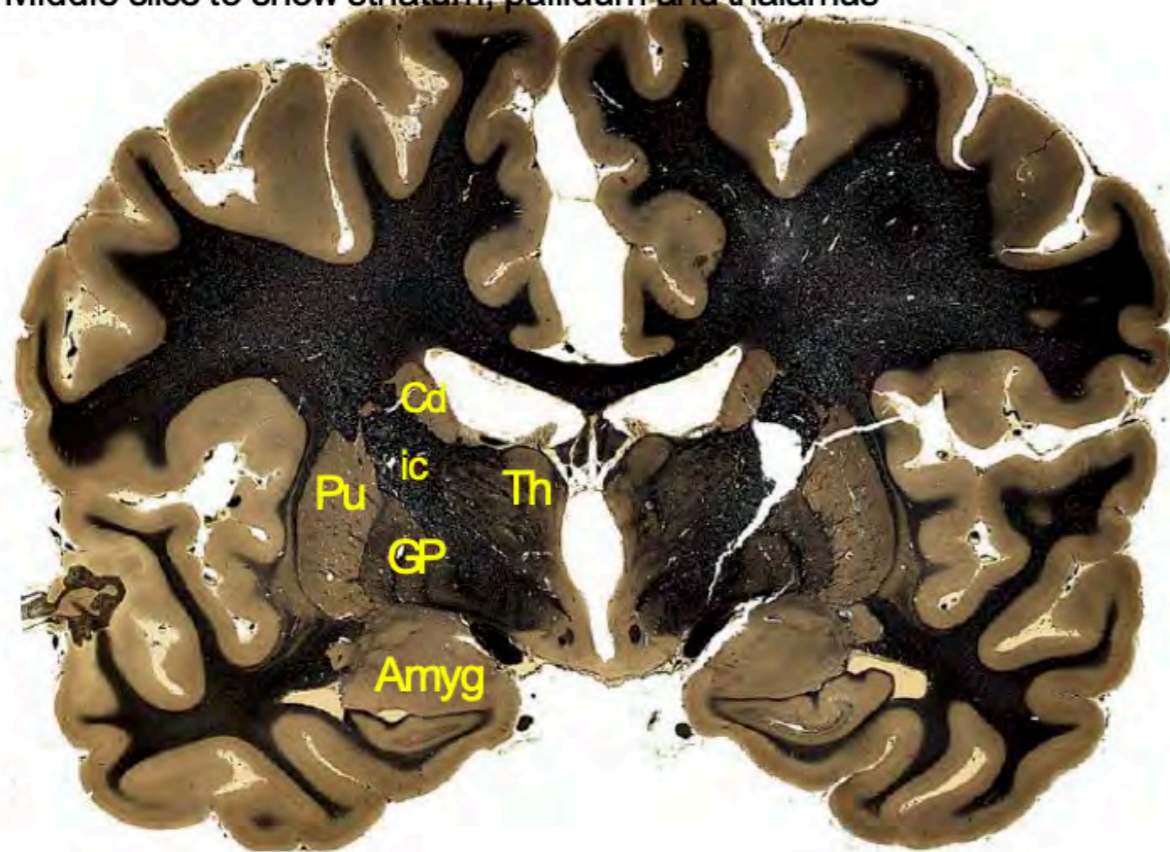
### Subpallial structures

Under the covering of the pallium are a number of large specialized neuron groups. The largest of these groups are the striatum and pallidum, which play essential roles in the control of movements. The smaller subpallial groups (the amygdala, septum, and preoptic area) are concerned with emotional expression and behavior patterns.

### Striatum and pallidum – the 'basal ganglia'

The largest of the subpallial groups are the striatum and globus pallidus. Traditional terminology refers to this pair as the 'basal ganglia.' Unfortunately, different books use the term basal ganglia in a variety of different ways, some adding the amygdala and other deep forebrain structures, and some even adding parts of the diencephalon and midbrain such as the zona incerta and substantia nigra. Because of this, it is best either to avoid the use of the term basal ganglia altogether or to make it clear when you are referring to the striatum and globus pallidus alone.

### Middle slice to show striatum, pallidum and thalamus



### Middle slice to show striatum, pallidum and thalamus.

The striatum contains two parts, the caudate nucleus and the putamen. On the medial side of the putamen is the pallidum, represented chiefly by the globus pallidus. Together the striatum and pallidum form a powerful motor control system, enabling the brain to choose from a 'library' of inherited stereotyped behaviors according to the need at any moment. The striatum receives a significant input from the motor cortex, and it in turn projects to the globus pallidus. The globus pallidus projects to the ventrolateral nucleus of the thalamus and the circuit is completed by the projection of this nucleus to the motor cortex. Another important input connection of the striatum is the dopaminergic pathway that arises from the substantia nigra. Damage to this dopaminergic projection is the underlying cause of Parkinson's disease.

A less well-known part of the striatum is the accumbens nucleus, which lies ventral to the rostral parts of the caudate and putamen. The accumbens nucleus also receives a dopaminergic projection from the brainstem, but in this case, it comes from the ventral tegmental area, which is medial to the substantia nigra. The dopaminergic projection to the accumbens forms the basis of an internal reward system in the brain.

### The amygdala

The amygdala lies deep to the piriform (primary olfactory) cortex on the medial side of the temporal lobe, just rostral to the hippocampus. The amygdala is a complex structure made up of many different subnuclei. The subnuclei of the amygdala can be divided into two main groups – a medial group that is interconnected with the olfactory system and a lateral group that is connected to circuits involved in emotional responses, particularly fear. The lateral group in the amygdala responds to sensations that signal danger. It can react by activating autonomic and endocrine centers, such as the 'fight or flight' mechanisms. Most of these circuits are closely interconnected with the hypothalamus. Fear and stress can generate very powerful, unconscious emotional memories through the amygdala. These unconscious fears are very difficult to suppress or erase.

Another major role of the amygdala is its control of hierarchical behavior (pecking order) in vertebrates. Social hierarchies are fundamental in animals that belong to large groups where dominance behaviors maintain the effective structure of the group.

There is a complex relationship between the amygdala and aggressive behavior, and the nature of aggressive behavior is often misinterpreted. Konrad Lorenz argued that the strongest forms of aggressive behavior are those that occur between members of the same species, usually related to attempts to establish a place in a hierarchy (Lorenz, 2002).

### A discredited term – 'The Limbic System'

In many textbooks, a section dealing with the amygdala and related structures is titled 'The Limbic System.' We strongly recommend you avoid using this term because it can be defined in many different and confusing ways. The term 'limbic' has its origin in 'le grand lobe limbique' of Broca. Broca wanted to draw attention to the curved belt of telencephalic structures that border the central parts of the forebrain (the word limbic refers to a borderland). This original definition of the 'limbic lobe' included the ventral hippocampus, the amygdala, the cingulate gyrus, and the fornix. However, in the contemporary literature, the limbic lobe is often said to include all the various parts of the hippocampal formation, the septum, the olfactory tubercle, and the bed nucleus of the stria terminalis, the amygdala, and the cingulate gyrus. Different authors add or subtract structures from the definition in what sometimes seems to be a random manner. Some go so far as to include the hypothalamus and parts of the brainstem. Their logic is that all structures that might be involved in emotions or primitive behaviors should be lumped together under this title. The result is so confusing that we strongly recommend that you avoid using the term 'limbic' altogether.

### The subcortical white matter

Deep to the cerebral cortex is a thick layer of white matter. In connectional terms, the axons in the cerebral white matter are of three types – association fibers, commissural fibers, and projection fibers. The association fibers run from one area of the cortex to another area of the cortex within the same hemisphere. They may be short (joining the cortex of adjacent gyri, for example) or may form long association bundles running from one lobe to another. The commissural fibers join cortical areas of one hemisphere to equivalent areas on the opposite side. The projection fibers travel downwards from the cortex to the striatum, pallidum, diencephalon, midbrain, hindbrain, and spinal cord, or upwards from the thalamus to the cortex.

### Forebrain commissures

There are four commissures in the forebrain, the largest of which is the corpus callosum, which connects the neocortical areas of the two sides. The hippocampal commissure (fornix commissure) connects the right and left hippocampal regions. The anterior commissure connects areas of the temporal lobes, including some olfactory areas. The small posterior commissure is located in the pretectal area of the diencephalon, adjacent to the midbrain.

**The corpus callosum** lies under the cingulate gyrus, above the septum, and the lateral ventricle. The rostral end is called the genu, the central part is called the body, and the thickened caudal end is called the splenium. The ventral tip of the genu forms the rostrum of the corpus

callosum. In most cases, fibers crossing in the corpus callosum connect symmetrical parts of the cortex. The fibers crossing in the genu of the corpus callosum reach the tip of the frontal lobe in a U-shaped formation called the forceps minor. Similarly, the fibers crossing in the splenium reach the tip of the occipital lobe in a larger U-shaped formation called the forceps major.

**The hippocampal commissure** (also called the fornix commissure) is located ventral to the corpus callosum.

**The anterior commissure** is located at the rostral end of the diencephalon in front of the anterior columns of the fornix. The anterior commissure is a very useful landmark in the study of sections of the forebrain: it lies at the rostral end of the diencephalon at the level where the interventricular foramen connects the lateral ventricle to the third ventricle. The preoptic area is ventral to the anterior commissure, which is the most ventral part of the subpallium, and caudal to the preoptic area is the rostral end of the hypothalamus. The anterior commissure is also a good marker for the rostral end of the hippocampus and the amygdala in human brain slices.

**The posterior commissure** is found in the caudal pretectal area. It links together a number of pretectal nuclei involved in eye reflexes. In the past, the posterior commissure was often mistakenly thought to belong to the midbrain, but gene expression proves it lies in the caudal diencephalon.

#### Questions for repetition

- Of what does the telencephalon consist of?
- What does the pallium comprise?
- What enables the human brain to undergo massive expansion?
- What separates the primary motor and the primary sensory areas?
- What layers make up the neocortex?
- Which part of the striatum is involved in the reward system?
- In which functions is the amygdala involved?
- What types of white matter tracks can be distinguished?

#### The Brodmann areas of the cortex

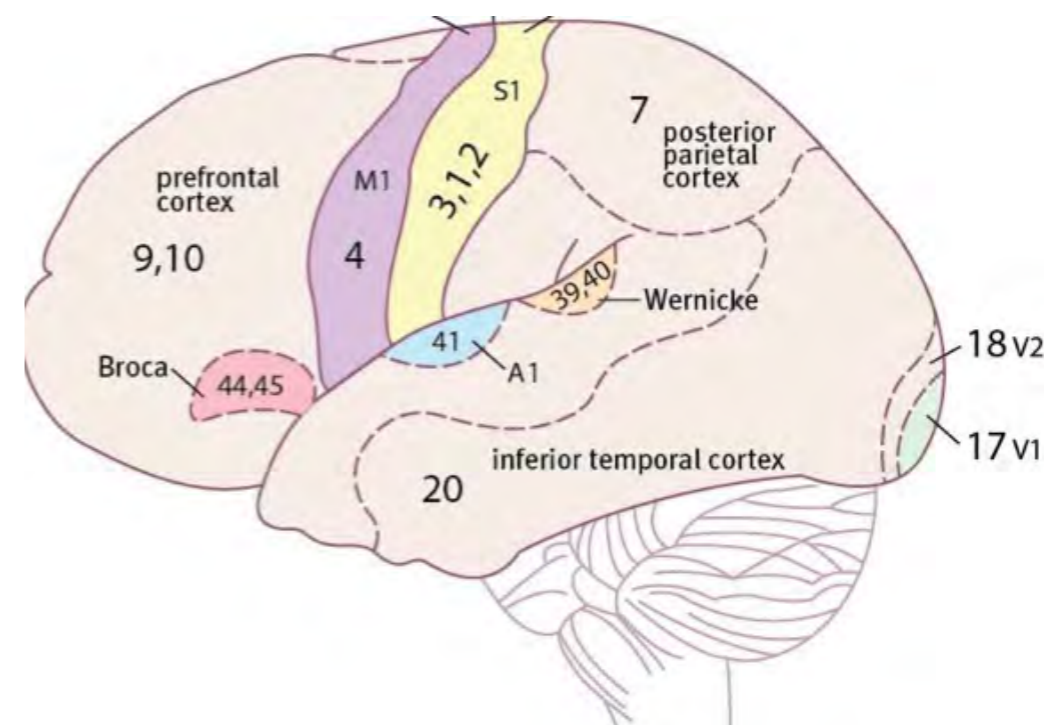
A number of anatomically distinct areas can be recognized in the human neocortex. Many modern studies estimate that there may be about 180 anatomically and functionally distinct areas in the human neocortex.

There have been several attempts over the past 150 years to define the major human cortical areas. The most influential is Brodmann's.

In 1910, Brodmann published a numbered list of about 50 different areas based on histological differences. This numbering system is still widely used today.

The most recognized Brodmann areas are the following:

- area 4 – primary motor cortex (M1) - located in the precentral gyrus
- areas 9 and 10 – the prefrontal cortex – located rostral to the primary motor cortex
- areas 3, 1, and 2 – primary somatosensory cortex (S1) - located in the post-central gyrus
- area 41 – primary auditory cortex (A1) – located on the upper surface of the superior temporal gyrus, mainly inside the lateral fissure
- area 17 – primary visual cortex (V1) – located on the medial surface of the occipital lobe in the upper and lower banks of the calcarine sulcus
- areas 45 and 44 - Broca's area (motor speech area) – located in the triangular and opercular parts of the inferior frontal gyrus, immediately rostral to the inferior part of the precentral gyrus in the dominant hemisphere
- areas 39 and 40 – Wernicke's area (speech comprehension area) – located on the upper surface of the superior temporal gyrus caudal to the primary auditory cortex in the dominant hemisphere. Most of Wernicke' area is inside the lateral fissure.



*Overview of important Brodmann areas.*

### Questions for repetition

- How many, functionally different neocortical areas are assumed nowadays?
- Which Brodmann areas are included in Broca's area?
- In which functions are Brodmann areas 39 and 40 involved?

## MOTOR SYSTEMS

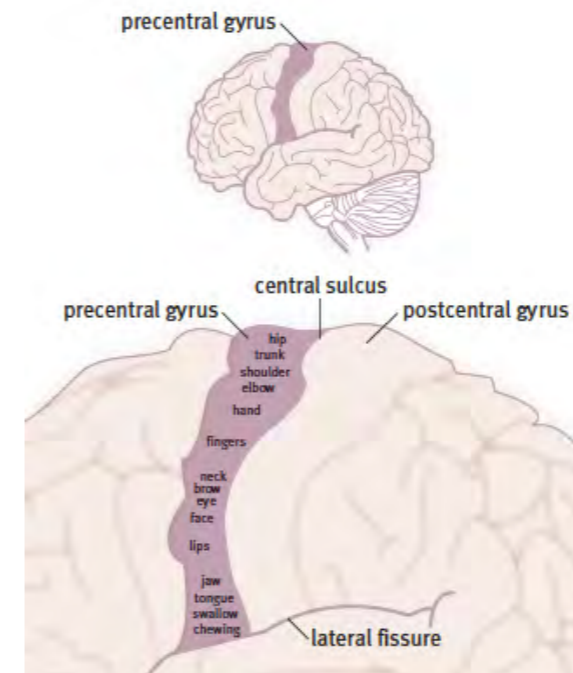
### Motor systems

The nervous system can respond to external challenges through muscle contraction, internal adjustments to heart rate and breathing, and secretion of hormones in response to stress and other bodily requirements.

### Control of skeletal muscles

The skeletal muscles are under voluntary control most of the time. However, in some cases, the contraction of these muscles is in the form of a reflex, such as when we burn our fingers in a flame. Reflexes are faster than the typical system of conscious control.

In humans, the central area for the control of the skeletal muscles starts in the primary motor area of the cerebral cortex, which is located in the precentral gyrus of the frontal lobe. Electrical stimulation of the motor cortex produces contraction of muscles on the opposite side of the body. The body parts are represented upside down on the precentral gyrus, with the head at the bottom, and the lower limb at the top, with the muscles of the leg and foot, represented on the extension of the motor cortex onto the medial surface of the hemisphere.



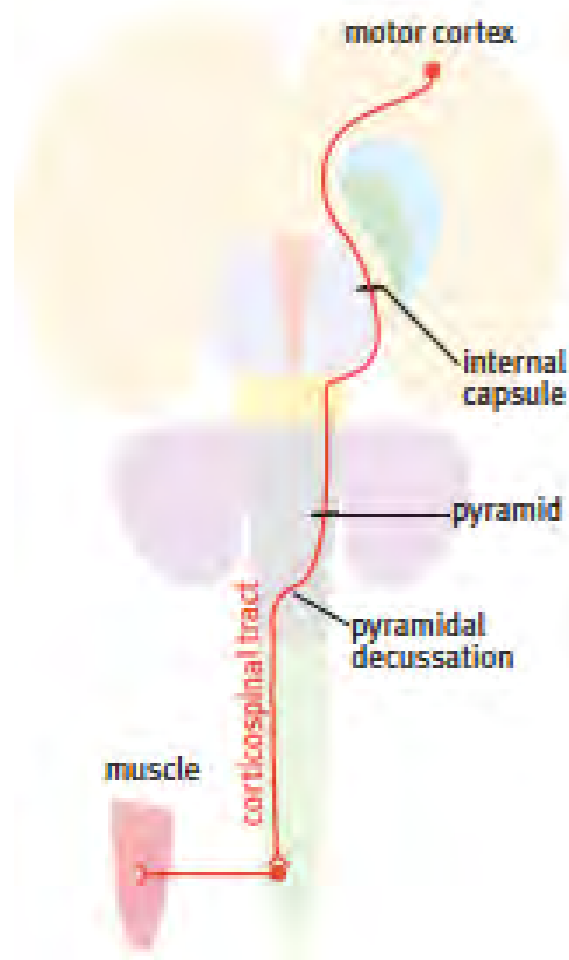
***The somatotopic pattern of control of muscles in the primary motor cortex. Note that the areas for control of the leg and foot muscles are on the medial side of the cortex.***

The motor cortex is connected to the motor neurons of the spinal cord by a long pathway called the corticospinal tract. The corticospinal tract arises from large pyramidal cells in the motor cortex. Their axons travel through the internal capsule, cerebral peduncle, the basilar pons, and the medullary pyramid to reach the caudal end of the hindbrain. At this point, most of the corticospinal fibers cross to the opposite side in the pyramidal decussation. Due to that, they make connections with motor neurons on the opposite side of the body from their cortical origin.

Because the corticospinal fiber bundles form the medullary pyramids, the corticospinal tract has traditionally been called the pyramidal tract. This term is in some ways unfortunate because, by coincidence, the cells of origin of the corticospinal tract are pyramid-shaped neurons in the motor cortex. Another reason to avoid using the term pyramidal tract is the unfor-

tunate and now discredited 'pyramidal/extrapyramidal' concept, which was an early but misinformed attempt to explain the organization of different parts of the motor systems.

*The concept of an **extrapyramidal system** became popular among neurologists in the early 20th century, who were trying to distinguish the motor problems arising from damage to the pyramidal (corticospinal) tract from other motor syndromes. They contrasted the direct (monosynaptic) projection of the cortex to motoneurons (the pyramidal system) with what they believed to be an alternative multisynaptic pathway from cortex to motoneurons, which they called the extrapyramidal system. They hypothesized that this multisynaptic pathway went from cortex to striatum and pallidum, then to various midbrain and hindbrain centers, and finally to the spinal cord. The problem is that the hypothesized chain of descending connections does not exist. It was famously debunked in 1962 by Nauta and Mehler. They showed that the globus pallidus projects almost entirely to the thalamus rather than to the midbrain and the hindbrain motor centers. Despite this, the 'extrapyramidal' concept lives on in textbooks and in lectures given by neurologists.*



### ***The course of the corticospinal tract from the motor cortex to the spinal cord.***

#### **Damage to the corticospinal tract**

Humans who experienced damage to the motor cortex or the corticospinal tract cannot perform tasks that require precise movements of individual fingers, such as writing, sewing, tying knots, and picking up small objects. Less precise movements, and those that involve larger muscle groups, are less severely affected. When a cerebral stroke damages the corticospinal

tract in humans, other nearby areas, such as the striatum, are also damaged. Because of this, the loss of fine movement is accompanied by hypertonia (stiffness or spasticity) and hyperreflexia related to striatal damage.

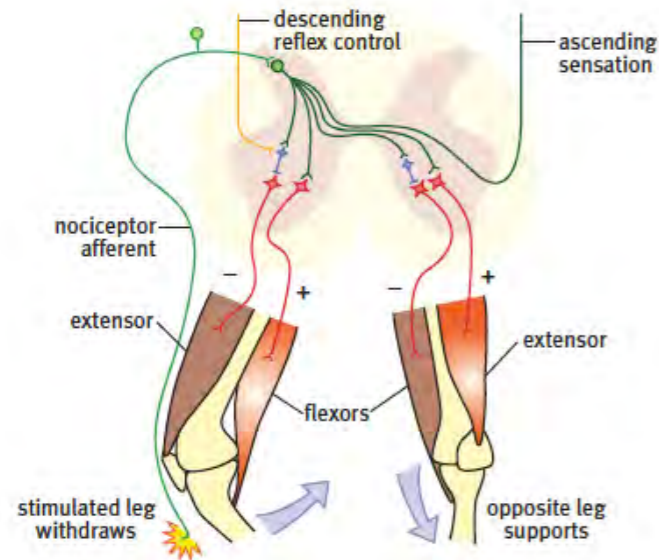
#### **The role of non-cortical motor centers – modules for motor control**

We plan movements conceptually, thinking in sequences and outcomes rather than joint angles and contraction of individual muscles. The brain translates high-level action plans into modular systems to manage the control of dozens of muscles needed to carry out a particular task to make this process more efficient. These modular control systems are found in the brain stem and spinal cord. These modules are pre-wired during brain development to produce semi-automatic movements like walking and chewing. This makes it easier for the motor cortex to get a result without the need to connect to individual motor neurons. During vertebrate evolution, complex behaviors and movement sets became organized in a hierarchy of modules. At the top of the hierarchy are survival behaviors - eating and drinking behaviors, defensive behaviors, reproductive behaviors, and movement patterns to explore the immediate environment. The most important centers for the control of survival behaviors are located in the hypothalamus.

#### **Brainstem and spinal cord modules for control of complex movements**

Each hypothalamic behavioral organizer connects with movement modules in the brainstem and spinal cord. For example, feeding may involve turning the head to look around, running to a food source, reaching and grasping, and licking and chewing. Each of these activities is sequenced by a particular part of the midbrain, hindbrain, or spinal cord. The hypothalamus activates a number of these movement modules in a coordinated program to achieve the desired behavior. The brainstem offers modules for orienting movements of the head and neck, licking, chewing, facial expression, vocalization, and control of breathing. The movement modules in the spinal cord include those that control posture, locomotion, reaching, and grasping.

An example of modular control at the spinal cord level is the withdrawal of the lower limb from a sharp pain in the foot, such as standing on a piece of broken glass. Interneuron groups of the spinal cord entirely handle this complex response, and the withdrawal movement occurs before the pain is even registered in the cerebral cortex. The primary response is to pull the foot away from the source of the pain, requiring contraction of hip flexors (psoas and iliacus) and knee flexors (hamstrings) while inhibiting the corresponding extensors to permit the movement. The problem with this response is that it will also cause a fall unless adjustments are made. The module takes care of this by contracting hip extensors, hip abductors, and knee extensors of the opposite leg to stabilize the body. In this way, ten or more muscles in each leg are either contracted or made to relax in order to achieve the whole pattern of movement needed to terminate a painful stimulus.



**Reflex actions following a painful injury to the right foot. On the right-hand side, the flexor muscles pull the foot away from the painful stimulus, and the extensors are inhibited. On the left side, the extensor muscles are activated to maintain stability.**

**Descending motor control pathways other than the corticospinal tract**

As well as sending fibers to the spinal cord in the corticospinal tract, the motor cortex sends axons to the basilar pons (corticopontine fibers) and the brain stem (corticobulbar fibers) in order to connect with the cerebellum and brain stem motor centers. Several centers in the brainstem give rise to descending tracts that end in the interneuron pools of the intermediate spinal gray matter. These are the rubrospinal, tectospinal, reticulospinal, and vestibulospinal tracts, each controlling different aspects of movement.

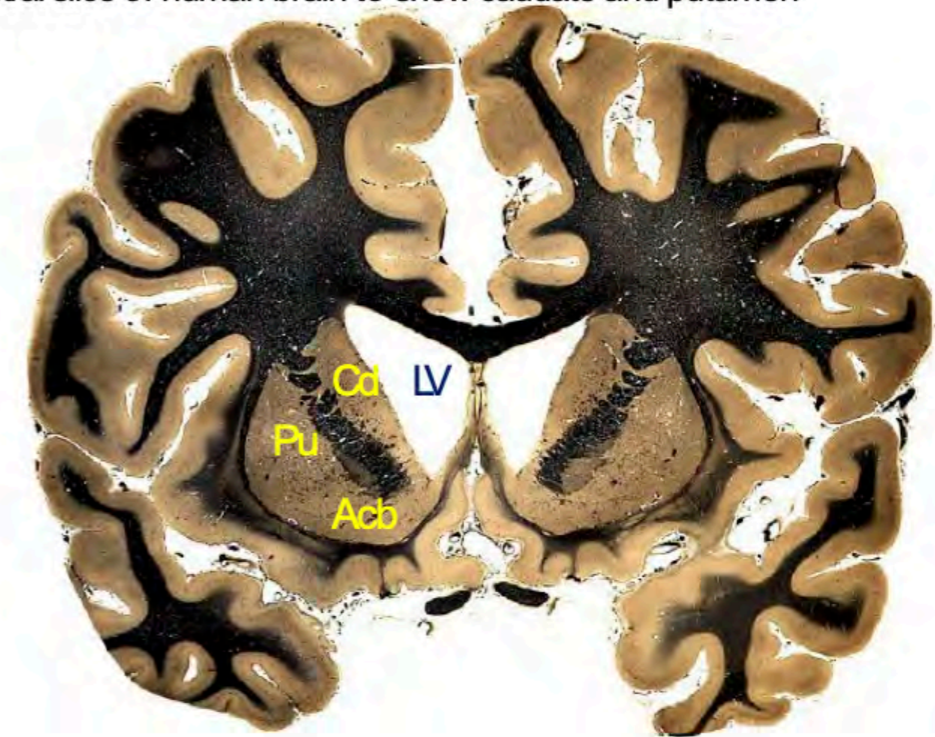
**The roles of the striatum and pallidum in motor control**

The striatum and the pallidum are large masses of gray matter that lie deep to the cerebral cortex. The striatum consists of three parts – the caudate nucleus, the putamen, and the accumbens nucleus. Medial to the putamen in the main part of the pallidum, called the globus pallidus. The globus pallidus is separated from the thalamus by the internal capsule. The accumbens nucleus lies deep to the rostral parts of the caudate nucleus and putamen.

The striatal and pallidal centers have a long evolutionary history and can be clearly identified in reptiles and birds. The striatum and pallidum are part of a major forebrain circuit of connections, regulating the form and style of movements.

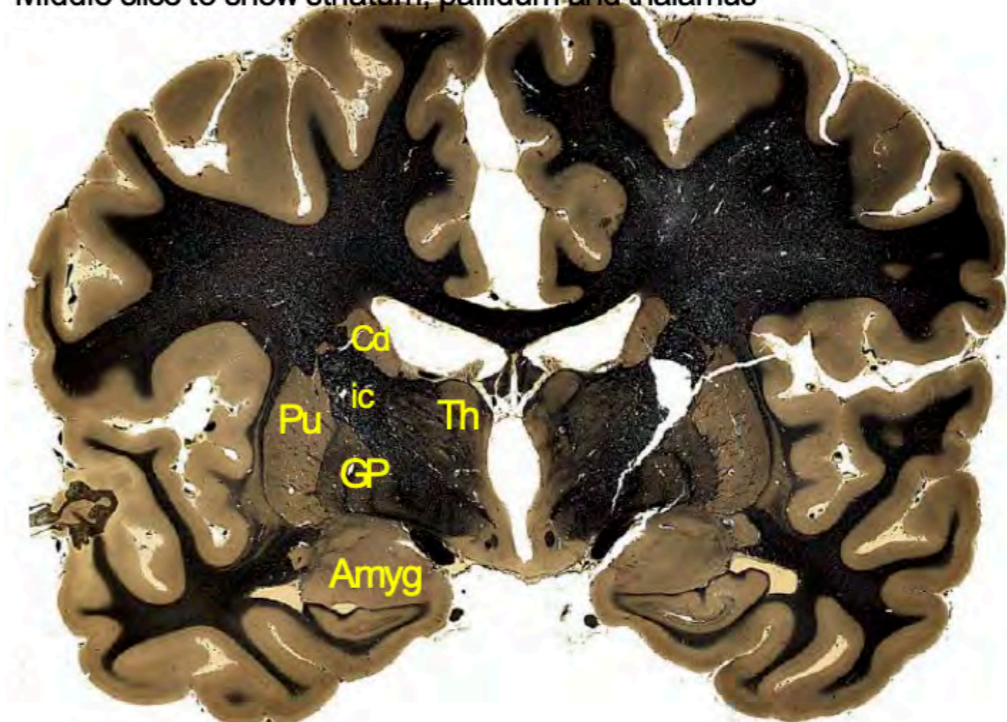
This circuit begins with neurons in the motor cortex, projecting to cells in the striatum. Striatal neurons project to the pallidum. The pallidum projects to the midbrain and the thalamus. The thalamic nucleus involved then projects back to the cerebral cortex, altering movements in the planning stage or while they are in progress. The substantia nigra is intimately connected with the striatum through the dopaminergic nigrostriatal pathway.

Rostral slice of human brain to show caudate and putamen



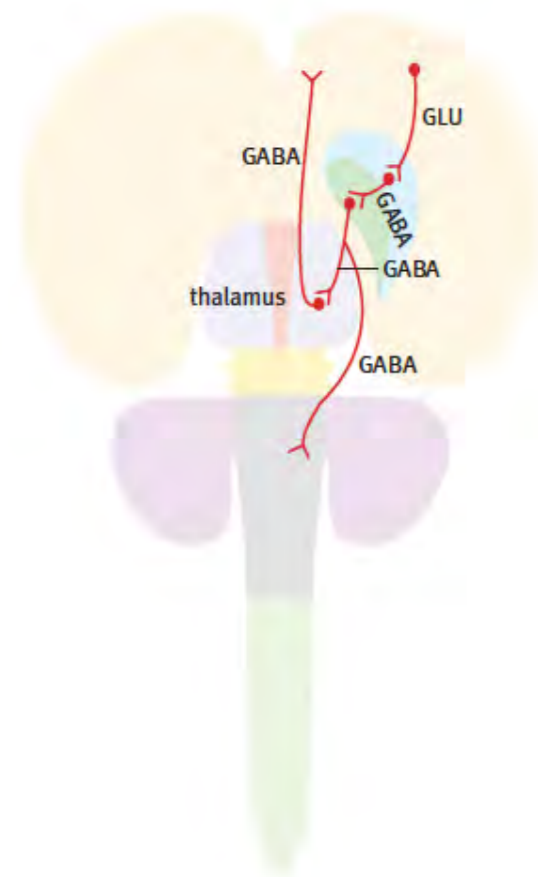
A rostral coronal slice showing the caudate (Cd), putamen (Pu), and accumbens (Acb).

Middle slice to show striatum, pallidum and thalamus



A coronal slice through the middle of the cerebrum showing the caudate nucleus (Cd), putamen (Pu), and globus pallidus (GP) and their relationship to the internal capsule (ic) and thalamus (Th).





***The connection circuit starting from excitatory glutamate neurons in the primary motor cortex (GLU). The cortical GLU neurons project to GABA neurons in the striatum. The GABA striatal neurons in turn project to GABA neurons in the pallidum. The circuit is completed by the projection of the pallidal neurons to the thalamus and the thalamic GABA projection back to the cortex.***

This set of connections underlies the production of predetermined movement patterns. Many species are known to have complex patterns of movement associated with mating and or displays of aggression. It seems possible that the striatal/pallidal complex is the main center for the initiation of these genetically determined movement patterns.

An interesting feature of the cells of the striatum and pallidum is that they influence the cortex by inhibiting thalamic neurons using the inhibitory neurotransmitter GABA. This makes them very different from the cortical neurons that connect to the striatum; these cortical neurons release the excitatory transmitter substance glutamate.

We do not have a clear idea of the precise role of the striatum and pallidum in humans, but we do have clues from cases in which these areas are damaged. The findings are disorders of the resting tone of muscles, difficulty starting movements, and unwanted involuntary movements. In Parkinson's disease, the input to the striatum from the substantia nigra is damaged. The result is a massive and disabling increase in muscle tone, accompanied by tremor in the hands, and great difficulty in starting movements. A severe form of damage to the striatum is seen in late-stage Huntington's disease, where the face, trunk, and limbs writhe continuously. In the case of cerebral palsy, the striatum and pallidum are likely damaged in the baby before birth.

The result is major disorders of muscle tone (often called spasticity) and a variety of involuntary movements.

#### The final common pathway for all motor systems – the motor neuron

All motor control systems act through the motor neurons: the final pathway to muscles. Large (alpha) motor neurons in the ventral horn of the spinal cord activate the skeletal muscles of the limbs and trunk. Similar alpha motor neurons in the midbrain and hindbrain activate the voluntary muscles of the head. Each alpha motor neuron is connected to many fibers in a skeletal muscle. When the alpha motor neuron fires, all of the fibers to which it is connected will contract. The motor unit is the combination of a single alpha motor neuron and the muscle fibers to which it connects. Activating alpha motor neurons is the only way to cause skeletal muscle fibers to contract. As a result, all the motor control systems described above achieve their effects by stimulating or suppressing alpha motor neurons. The English physiologist and Nobel prize winner, Charles Sherrington, coined the term 'final common pathway' to describe the role of alpha motor neurons.

#### Questions for repetition

- Of what parts does the striatum consist of?
- Describe the course of the corticospinal tract.
- What happens when the corticospinal tract is damaged?
- How is the globus pallidus separated from the thalamus?
- How is the substantia nigra connected to the striatum?

## SENSORY SYSTEM

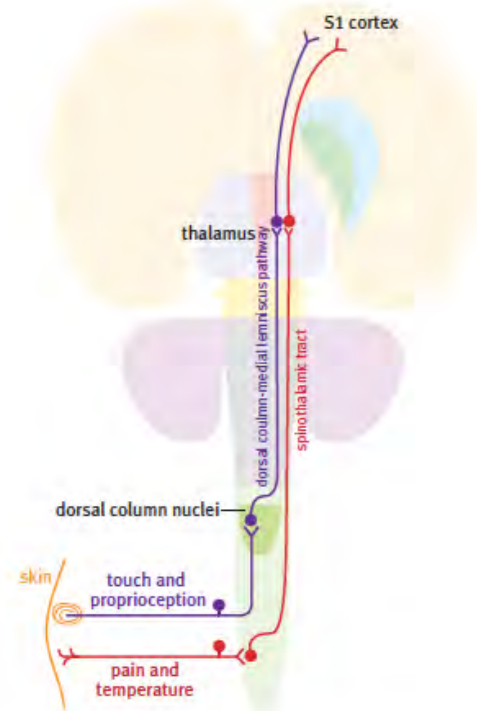
### The somatosory system

Somatic sensations come from the skin, muscles, joints, and bones. Somatic sensations from the head travel to the brain stem in the trigeminal nerve, whereas those below the head travel in spinal nerves to the spinal cord. Somatic sensations from the skin are touch, deep pressure, pain, and temperature.

#### Somatosensory pathways in the spinal cord

Both the spinothalamic tracts and the dorsal columns (gracile and cuneate fasciculi) convey somatosensory information from one side of the body to the cerebral cortex of the opposite side via the thalamus. Each of these systems is basically a chain of three neurons: the first neuron is a dorsal root ganglion cell with its central process entering the spinal cord to ascend for some distance before it synapses with the second neuron in the chain; the axon of the second neuron crosses the midline immediately and ascends to the thalamus; the third neuron sends its axon from the thalamus to the cerebral cortex.

The pain and temperature-sensitive fibers (spinothalamic tract) cross the midline a few segments above the level at which they enter the spinal cord. In contrast, fine touch and proprioception fibers (dorsal column-medial lemniscus pathway) do not cross until they reach the hindbrain.



**The spinal somatosensory pathways. Touch and deep pressure sensations are carried in the dorsal column-medial lemniscus system. Pain and temperature sensations are carried in the spinothalamic system.**

The dorsal column tracts carry touch, deep pressure, proprioceptive, and vibration sense information in the gracile and cuneate fasciculi - the gracile fasciculus mainly conveys information from the hindlimb. The cuneate fasciculus conveys information from the forelimb.

#### Dorsal column-medial lemniscus pathway

This is the main touch pathway. It transmits signals from low-threshold mechanoreceptors in the skin, muscles, and joints. This enables tactile discrimination, vibration detection, and proprioception (sense of position from joint and muscle receptors).

The main touch pathway's first-order (primary) neurons are located in the dorsal root ganglia. The axons of the ganglion cells carrying information from the lower limbs form the gracile fasciculus, while in the upper extremities, they form the cuneate fasciculus. The two fasciculi are collectively known as the dorsal columns.

The dorsal column axons ascend to the hindbrain, where they terminate in the gracile and cuneate nuclei. The axons leaving the cells of the gracile and cuneate nuclei cross the midline and form a compact bundle called the medial lemniscus. The medial lemniscus ascends through the brain stem to synapse with third-order neurons in the ventroposterior nucleus of the thalamus. The thalamic neurons send their axons to the primary somatosensory cortex in the postcentral gyrus.

#### Spinothalamic tracts

There are two spinothalamic tracts, lateral and ventral. Information about pain and temperature is conveyed by the lateral spinothalamic tract, while the ventral spinothalamic tract conveys touch sensation. The first-order neurons of the spinothalamic system are located in the spinal ganglia. The axons of these ganglion cells enter the spinal cord and ascend for a few segments before they synapse with second-order neurons in the substantia gelatinosa of the dorsal horn. The axons of the second-order neurons cross the midline in the anterior white commissure of the spinal cord to form the spinothalamic tracts. The crossed pain and temperature neurons form the lateral spinothalamic tract in the lateral column of the spinal cord. In contrast, the crossed touch neurons form the ventral spinothalamic tract in the ventral column of the spinal cord.

The spinothalamic tracts ascend along the spinal length and then travel through the brain stem until they reach the thalamus. In the thalamus, they synapse with third-order neurons in the ventroposterior nucleus. The axons of the ventroposterior thalamic neurons travel to the somatosensory cortex.

#### The cranial somatosensory system

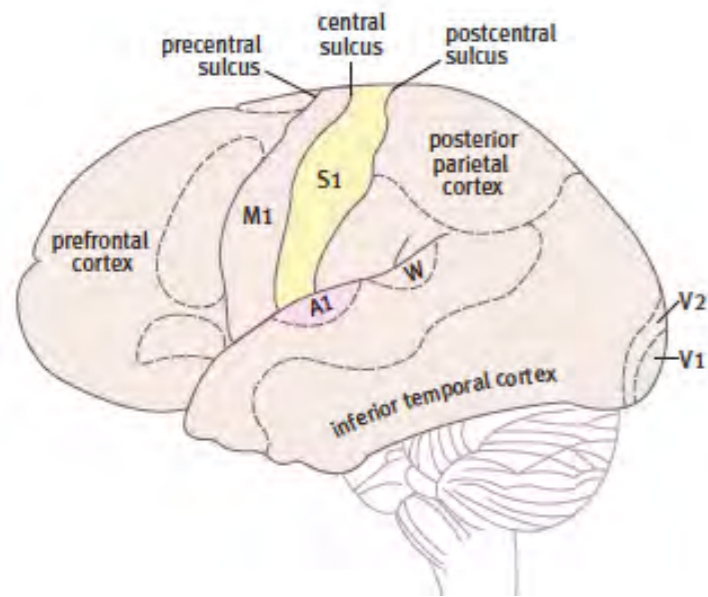
Almost all cranial somatosensory fibers in the head travel in the trigeminal nerve. The first-order trigeminal sensory neurons are located in the trigeminal ganglion in the skull base. The trigeminal ganglion axons enter the hindbrain through the side of the basilar pons. Some of these fibers synapse in the principal trigeminal sensory nucleus, which lies at the level of entry of the trigeminal nerve. However, many of the fibers descend in the hindbrain for considerable distances before they make contact with second-order neurons. Some of the descending fibers travel as far as upper cervical segments before they synapse.

The descending trigeminal fibers form the spinal trigeminal tract, and the trigeminal nuclear groups caudal to the principal nucleus are called the nucleus of the spinal trigeminal tract. Trigeminal fibers carrying touch sensation synapse in the principal sensory nucleus and the rostral part of the spinal trigeminal nucleus. Whereas those carrying pain and temperature sensation synapse in the caudal part of the spinal trigeminal nucleus.

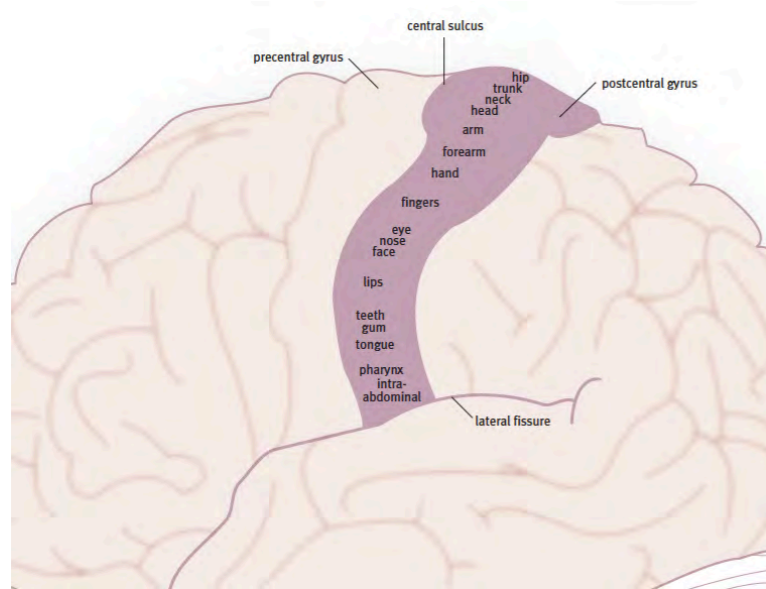
The axons of the neurons of the principal sensory nucleus and the spinal trigeminal nucleus cross the midline and ascend to the medial part of the ventroposterior nucleus thalamus. The ventroposterior nucleus sends its axons to the inferior half of the postcentral gyrus.

#### The primary somatosensory cortex

The primary somatosensory cortex is located in the postcentral gyrus, in Brodmann areas 3, 1, and 2. The somatosensory information reaching the postcentral gyrus is topically organized. Each individual region of the body is represented in a separate area on the gyrus, with the head at the bottom and the lower limb at the top.



*The primary somatosensory cortex (S1), which lies in the postcentral gyrus.*



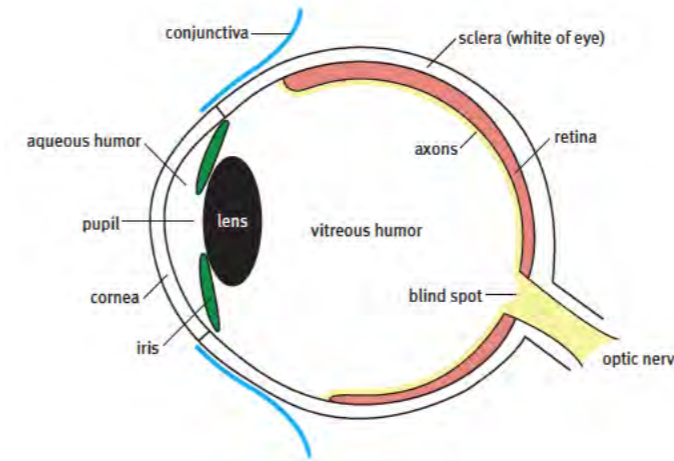
*The somatotopically organized representation of body sensations on the postcentral gyrus.*

#### Questions for repetition

- What information is summarised as the somatosensory system?
- How many neurons make up most somatosensory pathways?
- Where do the fibers that transmit information about temperature cross?
- How is touch sensation transmitted from the face?
- Which Brodmann areas does the primary somatosensory cortex comprise?

#### The visual system

The eye collects visual information to send to the brain. Before reaching the retina, light passes through the cornea, aqueous humor, lens, and vitreous humor. Visual images are focused by the cornea and lens before they reach the retina. The retina is enclosed in a thick fibrous layer called the sclera.



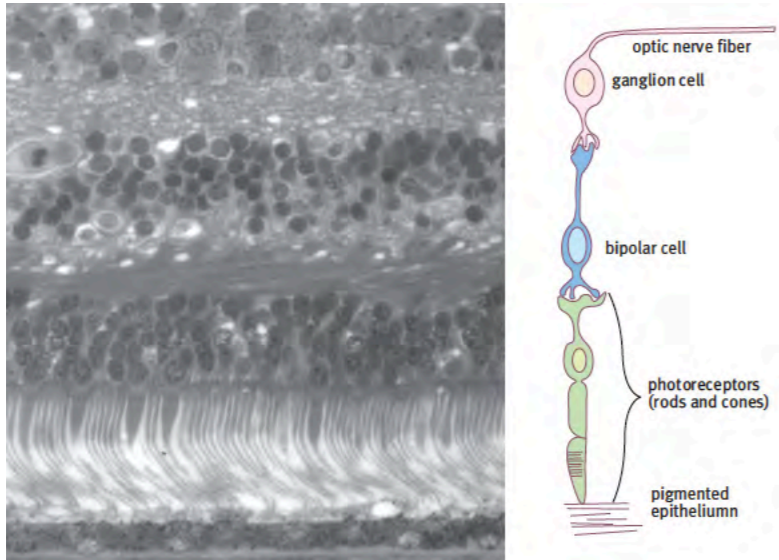
*A diagram of the eye.*

The light receptor cells of the retina, the rods and cones, lie in the deepest layer of the retina, so light must pass through the surface layers of the retina before it reaches the receptors. The human retina is in the form of a deep cup. Its outline represents about three-quarters of a sphere with a diameter of 22 mm. The human retina contains about 7 million cone cells and about 700 million rod cells. The cone cells are concentrated in a central area called the macula. They are responsible for high acuity and color vision. There are very few rod cells in the macula. Cones are sensitive to bright light and fall into three categories that respond to light in the spectrum's red, green, or blue parts. The rod cells do not discriminate between colors. Instead, they are sensitive to dim light and react quickly to moving objects entering the visual field.

Just medial to the macula is an area where the axons leave the retina forming the optic nerve. There are no photoreceptors in this area, so it creates a blind spot on the retina, about 1.5 - 2.0 mm in diameter.

#### The retinal cell layers

The cells of the retina are arranged in distinct layers, the most prominent of which are the photoreceptor layer, the bipolar layer, and the ganglion cell layer. As noted above, the photoreceptor layer is the deepest layer of the retina—furthest from the entry path of light rays. The receptor cells in this layer are the rods and cones. The light-sensitive processes of the rods are partly embedded in the pigmented epithelial layer. Superficial to the photoreceptor layer is the bipolar layer. The bipolar cells receive information from photoreceptors and send signals to ganglion cells. Amacrine cells and horizontal cells are also located in the bipolar layer. The function of the amacrine and horizontal cells is to modulate the signals reaching the bipolar cells. The ganglion cell layer lies on the superficial surface of the retina. Ganglion cells are the largest cells in the retina because they have long axons that travel to the brain in the optic nerve. The ganglion cell axons in the optic nerve reach centers in the hypothalamus (the suprachiasmatic nucleus), thalamus (the lateral geniculate nucleus), and the superior colliculus of the midbrain.



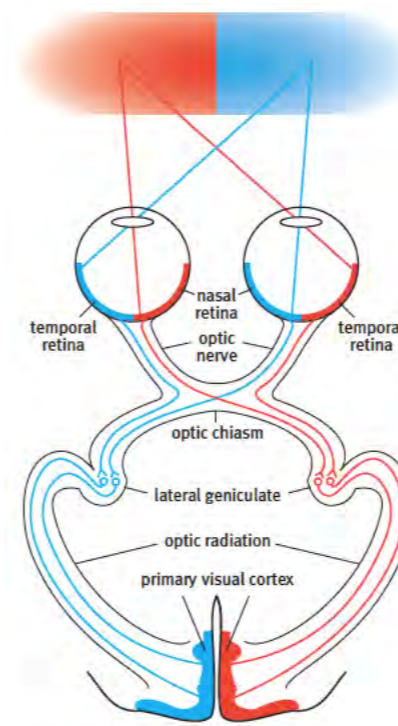
**The layers of the retina. On the left is a photomicrograph of a section through the retina with the ganglion cell layer above and the photoreceptor layer below. A diagram showing the connections between photoreceptors, bipolar cells, and ganglion cells is on the right.**

The intrinsic networks of the retina are capable of significant signal processing and consolidation of information. For example, ganglion cells on the edges of the retina receive information from a hundred or more rod cells, thus increasing sensitivity to dim light. By contrast, ganglion cells in the macula of a human retina receive input from only two or three cones, enabling the retina to resolve fine detail.

#### The organization of the projection from the retina to the brain

The ganglion cell axons from each of the two halves of the retina project to different sides of the brain. The axons from the medial (nasal) half cross the midline to project to the opposite side of the brain, whereas the axons from the lateral (temporal) half project to the same side of the brain.

Because light reaches the retina through a biconvex lens, the image reaching the retina is reversed. This means that the light received from the temporal half of the visual field falls upon the nasal parts of each retina and vice versa. The image from each temporal visual field (nasal retina) crosses in the chiasm to continue to reach the thalamus and cortex on the opposite side of the brain. The image from each nasal visual field (temporal retina) remains uncrossed and continues to reach the thalamus and cortex of the same side as the retina. The outcome is that the left-hand sides of the visual fields of both eyes run in the right optic tract, and the right-hand sides of the visual fields of both eyes run together in the left optic tract. The overall result is that each visual cortex receives information from the opposite side's visual fields. In other words, the right side of the retina of both eyes (temporal retina of the right eye and nasal retina of the left eye) projects to the right visual cortex, and vice versa.



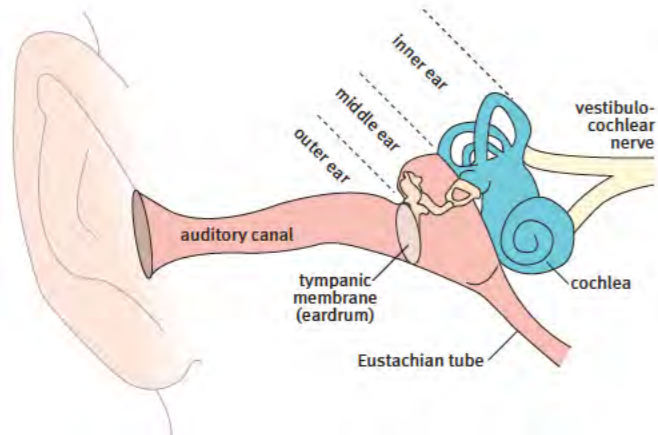
**A diagram showing the representation of the visual fields on the retina, the lateral geniculate, and the visual cortex. The overall effect is that the right half of the visual field is represented in the visual cortex and vice versa.**

#### Questions for repetition

- Describe the path of light through the eye.
- What is the characteristic stimulus for a rod?
- What causes the blind spot?
- Of what layers does the retina consist of?
- What is the anatomical structure of the visual pathway?

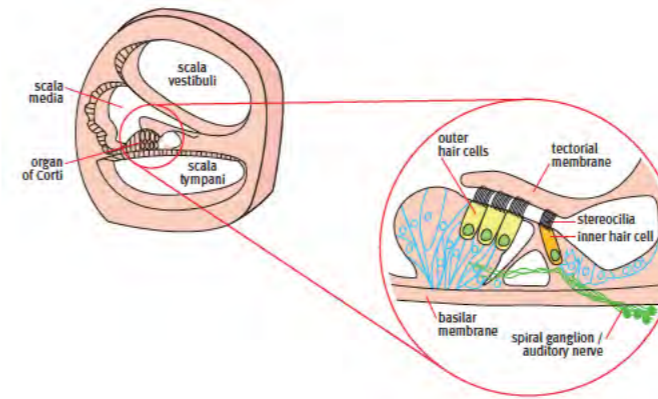
## The auditory system

The ear collects sound information to send to the brain via the vestibulocochlear nerve. The ear consists of three parts: the external ear consisting of the pinna, the auditory canal, and the tympanic membrane (eardrum); the middle ear, which contains the three auditory ossicles; the inner ear, which contains the cochlea.



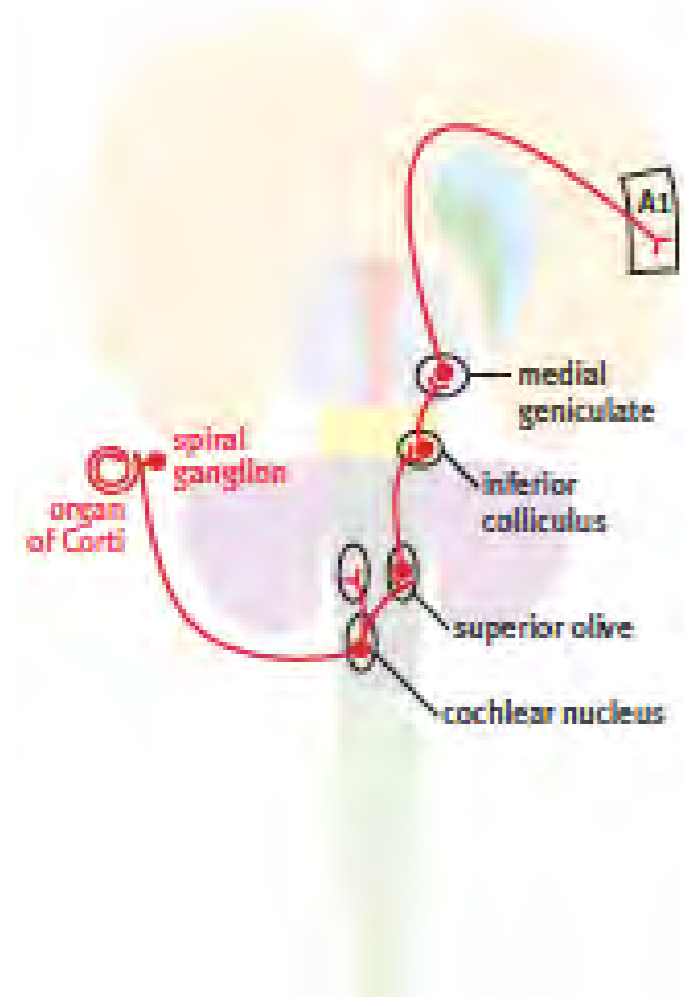**Sound enters the external ear through the auditory canal and causes the tympanic membrane to vibrate. This vibration is transmitted across the middle ear by three tiny bones, the malleus, incus, and stapes. The stapes transmits the vibration to fluid in the internal ear, and these vibrations eventually reach the cochlea. The cochlea is a bony shell that contains the sound receptors. Note that the middle ear is connected to the back of the throat by an air-filled canal called the Eustachian tube, or pharyngotympanic tube.**

The three auditory ossicles are named the malleus, incus, and stapes. They form a set of levers that mechanically transmits sound from the tympanic membrane to the oval window of the inner ear. Sound waves reach the inner ear then reach receptor hair cells in the cochlea. The cochlea is a bony case shaped like a spiral seashell. It contains the auditory receptor cells, which convert sound information into nerve impulses. Inside the cochlea are three spiral tubes, the scala vestibuli, the scala media, and the scala tympani. Each of these three tubes is filled with fluid. The scala media contains the auditory receptor apparatus (the organ of Corti), which sits on the basilar membrane. The outer hair cells of the organ of Corti are the receptor cells that are connected to sensory axons. The organ of Corti is tonotopically organized. The hair cells respond to different sound frequencies according to their position in the cochlea. The hair cells at the base of the cochlea respond to high frequencies, and the hair cells at the apex of the cochlea respond to low frequencies.



**Inside the cochlea are neuronal receptors grouped in a structure called the organ of Corti. The cochlea contains three fluid-filled tubes, and it is the middle one of these, the scala media, which houses the organ of Corti. Hair cells in the organ of Corti detect sound vibrations, and the information is transmitted to the hindbrain by the auditory (cochlear) nerve. The cell bodies of the cochlear nerve fibers are located in the spiral ganglion, which is embedded in the bony structure of the cochlea.**

The cell bodies of the auditory receptor neurons, which are connected to the organ of Corti, are located in the spiral ganglion, which is in the center of the cochlea. Each spiral ganglion cell has an incoming axon process connected to the organ of Corti and an outgoing axon process that travels in the auditory nerve to the brain stem. The auditory nerve axons terminate in the cochlear nuclei in the hindbrain. The cochlear nuclei project to the superior olivary complex. From there, the auditory information is sent to the inferior colliculus of the midbrain, where it is further processed before being sent to the medial geniculate nucleus in the thalamus. The medial geniculate projects to the primary auditory cortex (A1) on the upper surface of the superior temporal gyrus. The auditory pathway faithfully maintains the frequency map from the cochlea to the cortex so that the auditory representation that reaches the primary auditory cortex is still tonotopically organized. The brain stem auditory centers of both sides are interconnected across the midline. This bilateral network allows the brain to work out the position of an incoming sound. Because of these interconnections between the brain stem auditory nuclei, the primary auditory cortex receives information from both ears.



**The auditory pathway from the cochlea to the primary auditory cortex (A1).** Ganglion cells in the spiral ganglion receive information from the organ of Corti, and this information is transmitted centrally to the cochlear nuclei. Each cochlear nucleus is connected to neurons in the superior olivary nuclei of both sides. The superior olivary nuclei send axons to the inferior colliculus of the midbrain, which is in turn connected to the medial geniculate nucleus of the thalamus. The geniculate nucleus projects to the primary auditory cortex.

#### Questions for repetition

- How is the inner ear structured?
- In which anatomical structure are the sensory receptors for the "sound waves" embedded?
- What is the anatomical structure of the auditory pathway?
- Which thalamic nucleus is involved in the auditory pathway?

#### The vestibular system

The name 'vestibular' comes from the vestibule, which is a small bony space in the inner ear in which the vestibular receptors are located. The vestibule is next to the cochlea, and the two structures together are housed in the bony labyrinth of the inner ear.

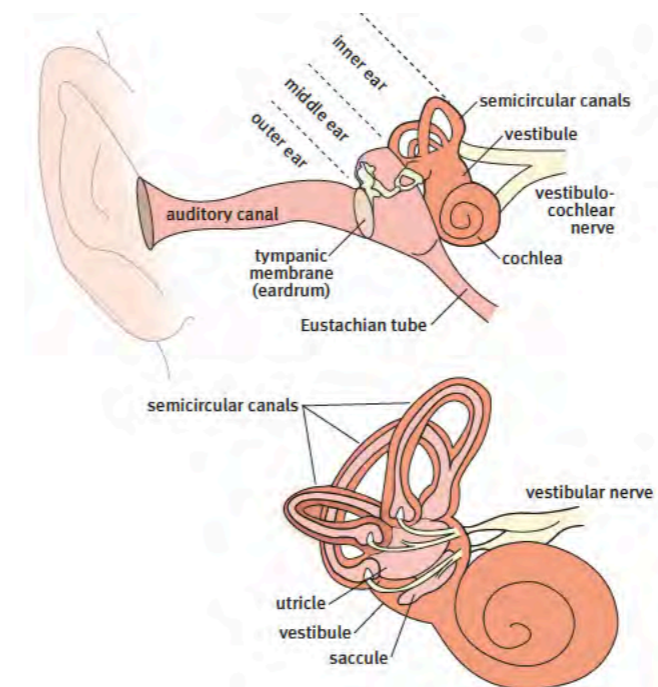
The main functions of the vestibular system are to maintain balance and coordinate eye movement with the head and body position. These functions are managed at a reflex level, with

constant adjustments being made to postural muscles and eye movement. Input from the vestibular system enables the eyes to track an object of interest, even when the body moves unpredictably. Eye movement coordination uses a network that interconnects the vestibular system with the visual system, the cerebellum, the spinal cord, and the motor neurons that control the eye muscles.

As well as controlling this complex reflex network, the vestibular system supplies information to the cerebral cortex about the body's position in space. This helps to give us a conscious appreciation of the position of the body in space. The somatosensory system also provides vital information on body position that contributes to our ability to maintain posture and balance. Some of the position sense information from the somatosensory system comes from touch receptors in the skin and deep pressure receptors in the feet.

#### The semicircular canals

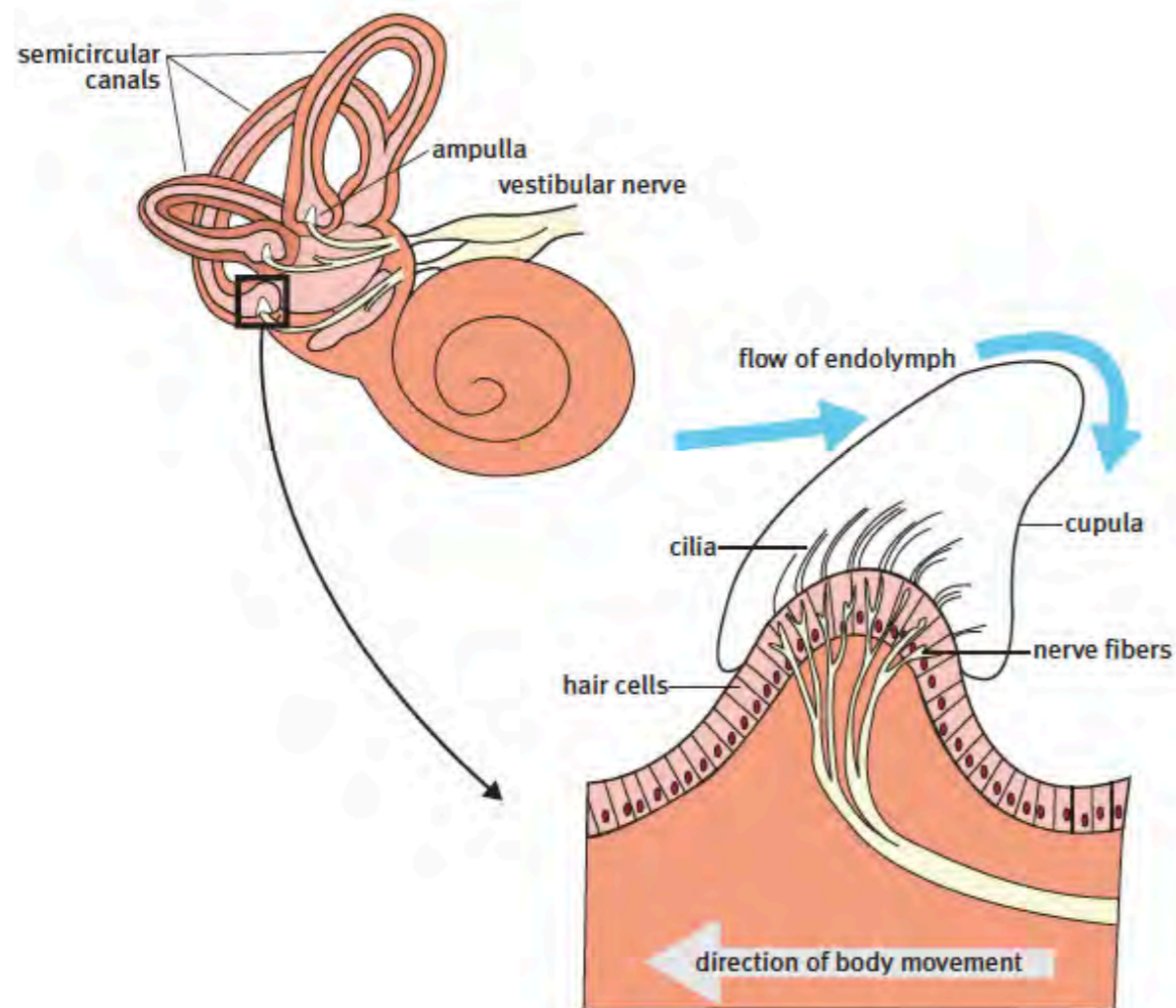
The vestibule contains two quite separate systems for gathering information on head position. One system, based on the semicircular canals, detects movement of the head in any direction. In contrast, the other system, based on the saccule and utricle system, is designed to register the position of the head when it is not moving. Therefore, the semicircular canal system can be described as the dynamic vestibular system, and the saccule/utricle system can be described as the static vestibular system.



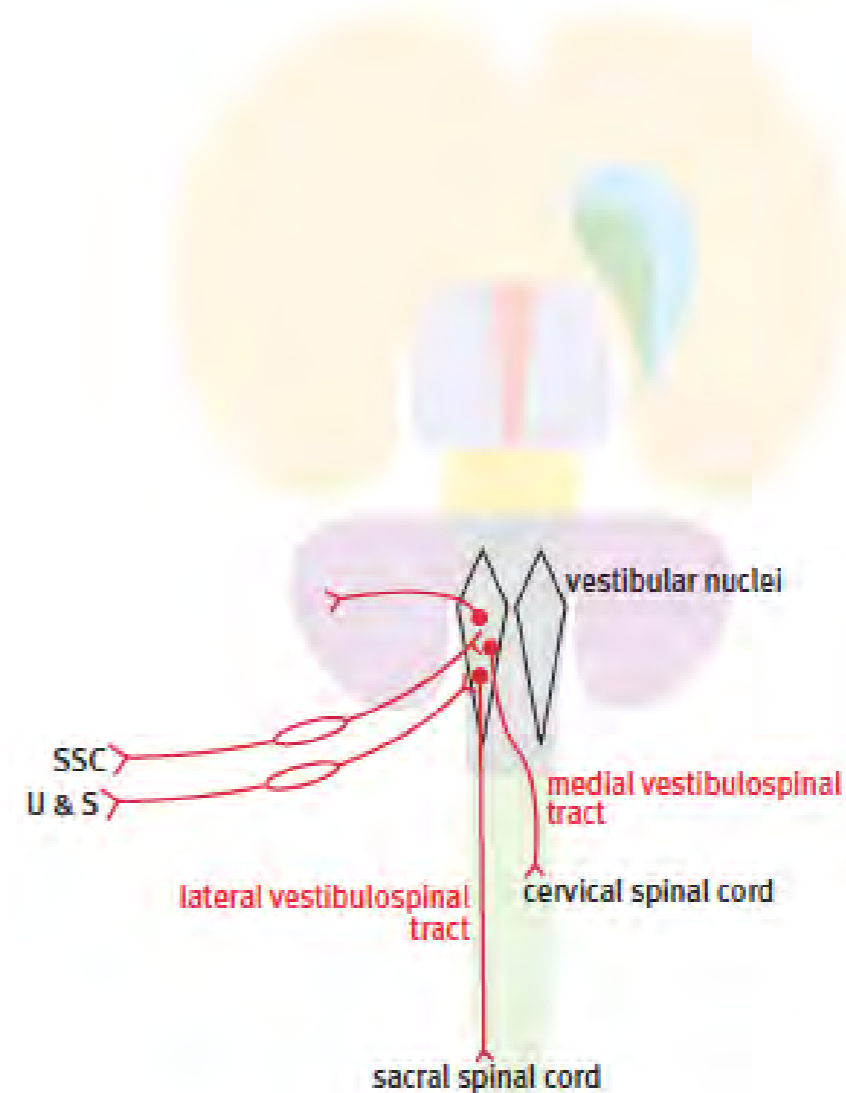
**Overview of the vestibular system.**

## Semicircular canals

The semicircular canals are three almost circular tubes containing a fluid called endolymph. Endolymph is also found in the cochlear duct in contact with auditory hair cells. Each semicircular canal is placed in a different spatial plane—one horizontal, one vertical close to the sagittal plane, and one vertical close to the coronal plane. No matter what direction the head moves in, it will cause fluid to move around in one or more of the three canals. Each canal has a widened area called the ampulla, which contains sensitive hair cells. The processes of the hair cells are embedded in a piece of jelly called the cupula. When the fluid moves in response to head motion, the cupula is dragged in the direction of fluid movement, twisting the processes of the hair cells. The twisting generates an electrical signal, which is carried to the hindbrain by the vestibular nerve.



*The hair cells of each semicircular canal are located in the ampulla. The cilia of the hair cells detect the movement of the endolymph. The information gathered by the hair cells is gathered by the axons of the vestibular ganglion cells. The vestibular ganglion cells are unusual in that they are true bipolar ganglion cells, not pseudounipolar cells as in the somatosensory and auditory systems. The central axon of the vestibular ganglion cell connects with the vestibular nuclei in the hindbrain.*



*Schematic overview of the vestibular pathways.*

## Sacculle and utricle

The saccule-utricle system is contained in a pair of recesses in the vestibule. The saccule and utricle each have a patch of hair cells called a macula. The processes of these hair cells are embedded in a plate of jelly, as are those of the semicircular canals, but in this case, the jelly contains calcium carbonate crystals called otoliths. The calcium-containing jelly plate is called the otolith membrane. When the head is stationary, the weight of the calcium-filled otoliths pulls the hair cells under the influence of gravity, and this, in turn, causes the hair cells to be stimulated. Other external forces such as rapid acceleration can also stimulate the hair cells in the macula. The receptor clusters of the saccule and utricle are set at right angles to each other so that they can establish the head's position at all times. The macula of the saccule is set in the vertical plane, so it is best placed to detect flexion and extension movements of the head. The macula of the utricle is set in the horizontal plane, so it is best placed to detect lateral tilting of the head. The information gathered by the receptors of the saccule and utricle is carried to the hindbrain by the vestibular nerve.

## Vestibular nuclei

The vestibular nuclei of the hindbrain occupy a large area in the floor of the fourth ventricle. They are strongly connected with the cerebellum, the spinal cord, and with the system that controls eye movement. The vestibular connection to the neck and eye muscles ensures that head and eye positions are constantly linked together. The medial longitudinal fasciculus is the brain stem pathway linking the eye muscle nuclei and the vestibular nuclei. The close relationship between the vestibular receptors and eye movement can be demonstrated by spinning someone around. If you sit someone in a rotating office chair and spin them around ten times at a moderate speed, then stop them abruptly, you will see the eyes flick from side to side in a movement called nystagmus. The eye movement happens because the fluid in the horizontal semicircular canal is still moving when the chair stops moving, and the eye muscle control system thinks that the head is still moving. It therefore responds with the side-to-side movement of the eyes. The subject will also complain that the room seems to be spinning around them; this sensation is called vertigo.

It is crucial to distinguish the sensation of vertigo from dizziness. Dizziness is a feeling of unsteadiness, while in vertigo, the world seems to be moving around you. Vertigo is often accompanied by feelings of nausea and may be associated with vomiting in severe cases.

## Vestibulospinal tracts

Two important descending tracts arise from the vestibular nuclei – the uncrossed lateral vestibulospinal tract, which reaches all spinal cord levels, and the crossed medial vestibulospinal tract, which ends in the cervical spinal cord. The medial vestibulospinal tract is primarily responsive to input from the semicircular canals, and it connects with the neck muscles to control head position. The lateral vestibulospinal tract is mainly responsive to information from the saccule and utricle; its primary role is to adjust posture in the limbs and trunk by activating extensor muscles to maintain balance.

## Vestibular representation in the cerebral cortex

While the main function of the vestibular system is the automatic control of body and eye position, the cerebral cortex receives vestibular information, which contributes to a conscious perception of body position. The main area receiving vestibular information in monkeys is located between the ventral part of the primary somatosensory cortex and the insula. It is assumed that an equivalent area exists in humans. Because the primary somatosensory cortex is in the postcentral gyrus of the parietal lobe, this area is referred to as the parietal-insular vestibular cortex. The input to this area is not exclusively vestibular; it also receives information from the visual system and from position-sense receptors in the neck.

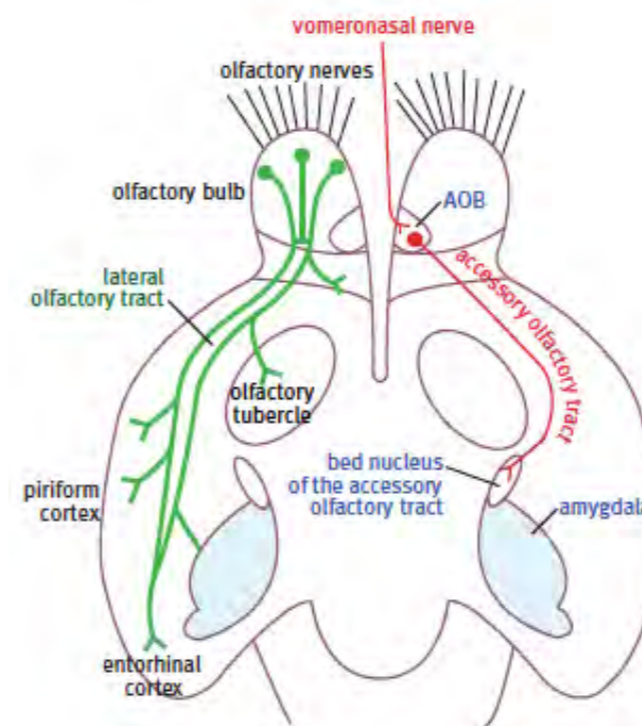
## Questions for repetition

- What are the two systems for determining head position?
- What are the differences between these two systems?
- Which brainstem pathway connects the control of the eye muscles and the vestibular nuclei?
- What is the primary function of the lateral vestibulospinal tract?

## Olfaction

In most mammals, the sense of smell (olfaction) plays a critical role in recognizing predators, partners, and offspring. The olfactory system has become less important in humans because we rely on a highly developed visual system. However, it is not often realized that a great deal of what we call taste is actually based on olfactory signals. When we have a nasal infection, and the olfactory receptors are injured or blocked, we lose about 90% of our ability to appreciate flavors. In many animals, olfactory input to the amygdala can initiate emotional responses, including aggression.

The olfactory epithelium of the nasal cavity converts information on odors into coded neural signals. Olfactory receptor neurons in the roof of the nose are subject to continual damage, and in rodents, they have an average lifespan of only 40 days. Because of this, they have to be constantly replenished from stem cells. Each olfactory receptor neuron sends an unmyelinated axon through holes in the ethmoid bone in the roof of the nose to reach the olfactory bulb.



*The main olfactory projection is diagrammatically shown on the left of the picture. Fibers from the olfactory bulb travel in the olfactory tract to reach the primary olfactory cortex (piriform cortex), the entorhinal cortex, and part of the amygdala. The right side of the diagram shows the accessory olfactory pathway, which does not exist in humans but is an important structure in many mammals.*

In addition to the main olfactory system, many mammals (but not humans) have a second olfactory system concerned with detecting pheromones. Pheromones are signaling chemicals released into the environment to cause behavioral changes in nearby individuals. Insects use pheromones to signal a wide range of situations, including sexual readiness, alarm, and to mark a trail. Most mammals have a small pheromone detecting system called the accessory olfactory system. It is primarily related to sexual signaling. This system is not present in humans.

The pheromone-sensitive area in the nose is called the vomeronasal organ. Removal of the vomeronasal organ in juvenile male mice does not impair food-finding abilities but does



impair their ability to recognize sexual signals from potential mates. Axons of receptor neurons in the vomeronasal organ project exclusively to the accessory olfactory bulb (AOB) adjacent to the main olfactory bulb. The output of the accessory olfactory bulb is to a special nucleus superficial to the amygdala, called the bed nucleus of the accessory olfactory tract.

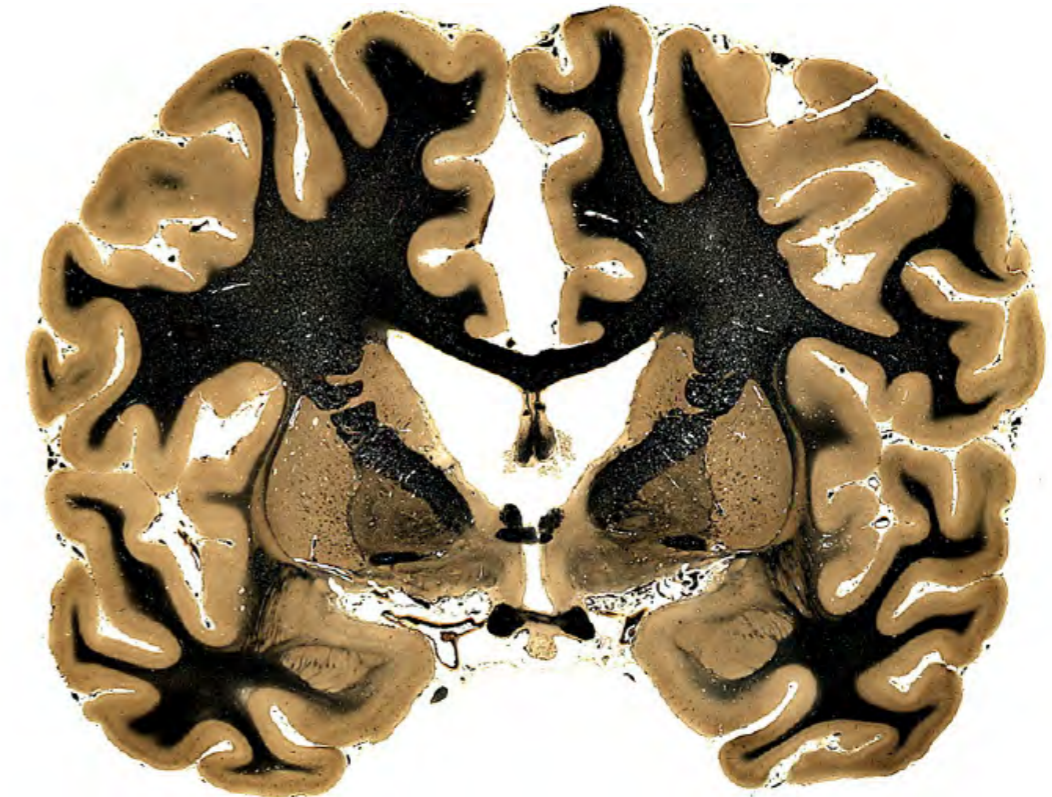
### Projections from the olfactory receptors to the brain

Nerve fibers connected to the olfactory receptor cells in the roof of the nose form twelve to twenty olfactory nerve bundles. These nerve bundles travel through a series of bony canals in the ethmoid bone to reach the olfactory bulb on the ventral side of the frontal lobe. Because the olfactory system is an extension of the forebrain and not a typical nerve, it is surrounded by meninges and cerebrospinal fluid. Fractures of the bony roof of the nose can therefore result in meningeal tears and cerebrospinal fluid leakage. The fluid leaks out through the nose, and the meningeal tear can result in potentially fatal bacterial infection in the cerebrospinal fluid space around the brain.

Fibers of the olfactory bulb continue to form the olfactory tract, which lies in a groove on the ventral surface of the frontal lobe. The olfactory tract ends by dividing into a medial and a lateral branch. The larger lateral branch (called the lateral olfactory tract) ends mainly in the primary olfactory cortex. The primary olfactory cortex is traditionally called the piriform cortex. In humans, the primary olfactory cortex is located in a gyrus called the uncus. The uncus is the most rostral part of the parahippocampal gyrus of the medial side of the temporal lobe. The uncus sits on the medial surface of the amygdala and is rostral to the hippocampus. Some olfactory tract fibers cross in the anterior commissure pathway to connect one olfactory bulb to that of the opposite side.

The blood supply to the uncus can be cut off during a difficult birth when pressure on the head during labor pushes the temporal lobe against the dural roof of the cerebellum. This can damage the underlying amygdala and may result in an atypical form of epilepsy later in life, called temporal lobe epilepsy or uncinate epilepsy.

The olfactory ventricle is a small space filled with cerebrospinal fluid in the middle of the olfactory bulb. It is formed from an extension of the lateral ventricle. In rodents, an area directly under the lateral ventricle, the subventricular zone, produces stem cells that migrate forward from the lateral ventricle into the olfactory bulb. They provide a continual source of new neurons for the olfactory system throughout adult life. This cell group is called the rostral migratory stream. The rostral migratory stream and the hippocampus are the only places where postnatal neurogenesis occurs in the brain. A rostral migratory stream has been shown in the postnatal human brain, but it is relatively small and becomes even smaller as the brain matures.



*The olfactory (piriform) cortex is in a gyrus called the uncus. It lies at the rostral tip of the parahippocampal gyrus of the temporal lobe. The olfactory cortex is superficial to the amygdala and is rostral to the hippocampus. The word uncus means a hook, which describes the shape of this small gyrus.*

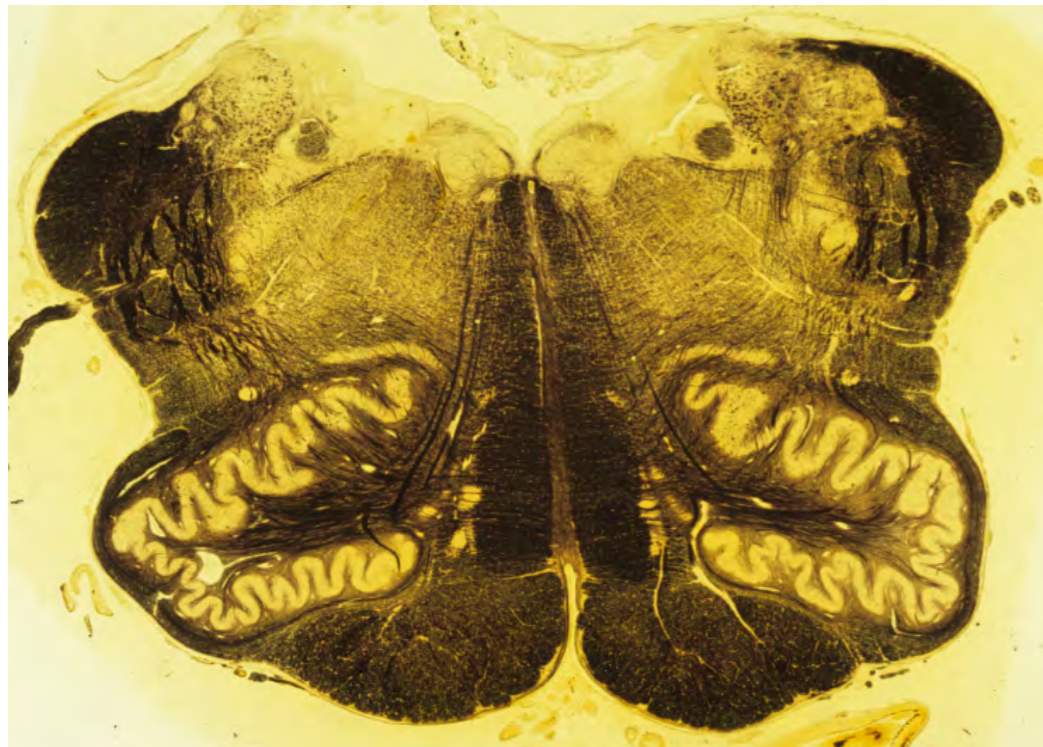
### Questions for repetition

- Which sense is extremely closely related to the sense of smell?
- How can mammals also perceive pheromones?
- Is the olfactory nerve built like a peripheral nerve?
- What is the primary olfactory cortex in humans called?
- Are the receptor neurons of the sense of smell a stable tissue?

## Taste

Taste receptors in the tongue send information via the facial and glossopharyngeal nerves to the hindbrain. The taste receptors of the anterior two-thirds of the tongue are connected with sensory fibers of the facial nerve. The taste receptors of the posterior third of the tongue are connected with sensory fibers of the glossopharyngeal. Not surprisingly, the facial and glossopharyngeal nerves also control the salivary glands. The glossopharyngeal nerve supplies the large parotid gland, and the facial supplies the smaller submandibular and sublingual glands with parasympathetic secretomotor fibers.

The taste sensory fibers in the facial and glossopharyngeal nerves form a distinct bundle in the hindbrain called the solitary tract, which lies between the dorsal nucleus of the vagus and the spinal vestibular nucleus. The hindbrain taste nucleus surrounding the solitary tract is called the nucleus of the solitary tract.



***The solitary tract stands out in this hindbrain section because it is made up of dark-stained myelinated fibers in an otherwise cellular area occupied by cranial nerve nuclei (arrow).***

The nucleus of the solitary tract projects to the medial part of the ventroposterior nucleus of the thalamus and the taste information is then sent from the thalamus to the insular cortex and the frontal operculum.

The taste receptors in the tongue have only a limited range of perception (salt, sweet, sour, bitter, and umami), and much of what we think of as 'taste' is actually based on information from the olfactory system. Odors from food in the mouth reach the olfactory receptors in the roof of the nose. The importance of the olfactory information in appreciating the taste of food becomes obvious when an infection blocks olfactory reception in the nose, such as happens with the common cold. With no olfactory reception, food seems to lose almost all its taste.

## Questions for repetition

- Which nerves innervate the taste cells of the tongue?
- What is the name of the fusion of the nerve fibers of the taste cell innervating nerves?
- Why can we taste worse when we have a cold?

## THE AUTONOMIC NERVOUS SYSTEM

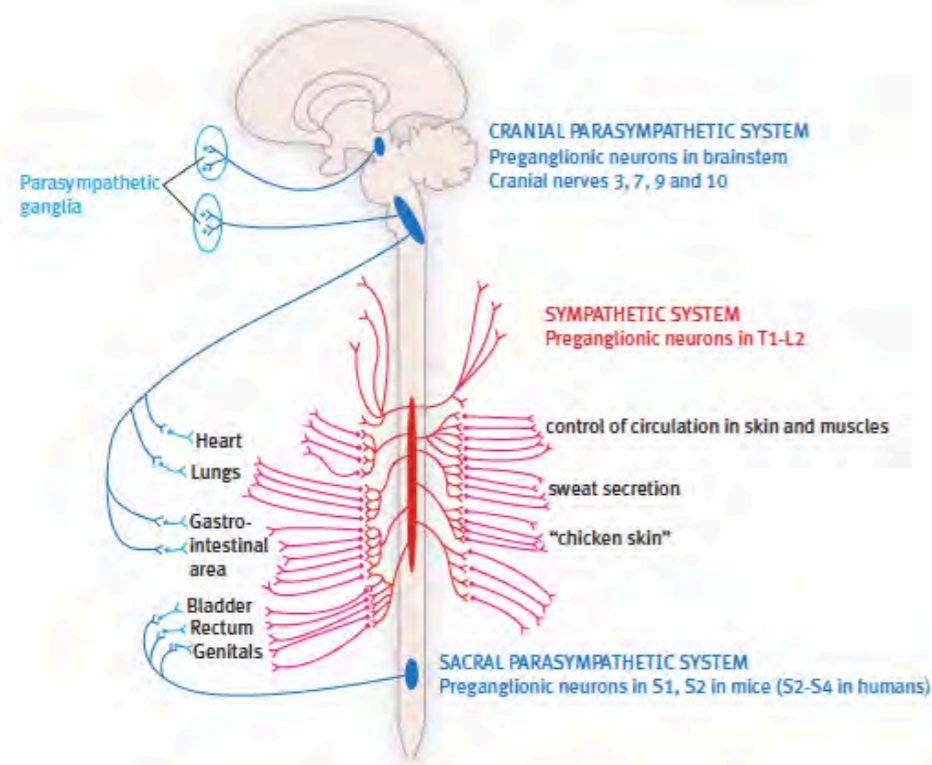
### The autonomic nervous system (ANS)

The effector systems that control the internal organs, glands, and blood vessels are collectively called the autonomic motor system because most of their functions are automatic and involuntary. They can also be called the visceral motor system to distinguish it from the somatic motor system that controls the voluntary muscles. The autonomic motor system is divided into sympathetic and parasympathetic groups based on function and anatomy. The sympathetic group is involved in the control of the arterial system and emergency (fight or flight) responses. In contrast, the parasympathetic group controls the normal day-to-day functions of the internal organs, such as salivation and digestion. Finally, the local neuron networks which coordinate the actions of the stomach and intestines are often grouped under the name enteric nervous system.

### Location of the sympathetic and parasympathetic motor centers

Whereas the motor neurons that supply the voluntary muscles are found in all regions of the brain stem and spinal cord, the autonomic motor centers occupy only restricted areas: the sympathetic motor centers are only located in thoracic and upper lumbar spinal cord segments (T1 to L2), and the parasympathetic motor centers are only found in the brainstem and in the sacral spinal cord. The cervical spinal cord, the coccygeal spinal cord, and most of the lumbar spinal cord contain neither sympathetic nor parasympathetic motor centers. The restricted origin of the sympathetic and parasympathetic motor systems poses a challenge for distribution since each system must supply structures from head to tail. The sympathetic and parasympathetic systems possess different solutions to distribute their activity to all appropriate parts of the body.

The sympathetic system arises from spinal nerves T2 to L2, but it spreads its influence through the sympathetic chain, which extends from the base of the skull to the pelvis. The parasympathetic system has its origins in the brain stem and the sacral spinal cord. Therefore, its solution is through the long course of the vagus nerve, which supplies thoracic and abdominal viscera from the neck to the pelvis. In the pelvis, it meets the sacral parasympathetic outflow from sacral nerves 2, 3, and 4.



**A diagram showing the distribution of the sympathetic nervous system (in red) and the distribution of the parasympathetic nervous system (in blue).**

#### Autonomic ganglia

In the somatic motor outflow, a single motor neuron connects the brain stem or spinal cord to a target muscle, whereas, in the autonomic nervous system, the motor outflow is formed by a two-neuron chain. The first autonomic motor neuron in the chain is located inside the brainstem or spinal cord; it sends its axon to a second effector neuron located in a ganglion outside of the central nervous system. The axon of the second neuron then innervates the target organ. The two-neuron system enables a single autonomic motor neuron to trigger hundreds of ganglionic effector neurons, producing widespread effects, such as arterial constriction to raise blood pressure.

Because the second motor neurons in the autonomic chain are clustered together in ganglia, the first neuron is called preganglionic, and the second neuron is called ganglionic. In the case of the sympathetic nervous system, the ganglia are close to the spinal cord, so the preganglionic cells have only short axons, and the ganglionic neuron axons are long. In the case of the parasympathetic nervous system, the motor ganglia are located very close to the target organs (some are even embedded in the walls of the target organs), and so the axons of the preganglionic cells are often relatively long, and the ganglionic axons are very short.

#### Functions of the sympathetic nervous system

The sympathetic nervous system is often described as a fight or flight system. It rapidly mobilizes critical bodily systems in times of emergency or stress, preparing the body for action by raising blood pressure, relaxing and opening airways, mobilizing energy sources, and temporarily shutting down digestion. Most importantly, it increases blood flow to muscles by shutting down blood flow to the skin and intestines.

The sympathetic nervous system can increase its influence over the blood vessels of the body by triggering the release of adrenaline and noradrenaline from the adrenal medulla. These two hormones have essentially the same effect as the postganglionic sympathetic nerves, but because they remain in the bloodstream, these hormones amplify and prolong the sympathetic actions and can influence cells that are not directly innervated by sympathetic nerves.

#### Sympathetic distribution

The preganglionic sympathetic neurons are found only in the middle region of the spinal cord, from the second thoracic segment to the first lumbar segment. Distribution to more rostral and caudal areas of the body is achieved by the existence of the sympathetic chain – a long system of nerves that runs alongside the bodies of the vertebrae. The sympathetic motor ganglia are embedded in this chain, with approximately twenty ganglia on each side. From the ganglia, postganglionic sympathetic fibers are distributed to all levels of the head and trunk and also to the limbs.

#### Functions of the parasympathetic nervous system

The parasympathetic nervous system is responsible for the normal day-to-day functions of the internal organs (a role which can be described as 'rest and digest'). Parasympathetic actions on the cardiovascular system are opposite to those of the sympathetic nervous system; the parasympathetic outflow lowers the heart rate and blood pressure. The parasympathetic nervous system does not send nerves to the limbs, so its role is restricted to the glands and organs of the head and trunk. It is also responsible for penile erection and bladder emptying.

#### Parasympathetic distribution

The cranial parasympathetic nerves supply the pupil and ciliary muscle (oculomotor nerve), small secretory glands of the eye and nose, small salivary glands (facial nerve), the parotid gland (glossopharyngeal nerve), and organs of the neck, thorax and abdomen (the vagus nerve). The vagus parasympathetic supply goes to the larynx, esophagus, lungs, heart, stomach, and the small and large intestines. The sacral preganglionic neurons supply effector neurons in the sigmoid colon, rectum, bladder, and genitalia.

#### Transmitter substances in the autonomic nervous system

All sympathetic and parasympathetic preganglionic motor neurons are like somatic motor neurons in that they use acetylcholine as their transmitter substance. The parasympathetic ganglionic neurons are also cholinergic. However, the sympathetic ganglionic effector neurons are noradrenergic.

#### Higher autonomic control

The motor neurons of the autonomic nervous system are regulated by centers in the hypothalamus and brainstem. These centers control vital functions of the cardiovascular and respiratory systems, as well as salivation, swallowing, digestion peristalsis, defecation, and urination. At a level above the brainstem, the hypothalamus triggers these autonomic functional centers as part of more significant behavioral responses, such as those involved in aggression. Anger is associated with increases in heart rate, blood pressure, and respiratory rate.

#### The enteric nervous system (ENS)

The networks of neurons embedded in the wall of the gut, which regulate and coordinate its activity, are called the enteric nervous system. This subdivision of the autonomic nervous system deserves a unique name because it is so large. In humans, it contains 200-600 million neurons, more than in the entire spinal cord. The enteric nervous system controls the contractions and secretions of the stomach, intestines, and other digestive organs. Although the central autonomic nervous system influences the ENS, it is capable of independent action through its own reflex systems. The enteric nervous system is also functionally linked to the body's immune system to help defend against invasive microorganisms in the gut. In many ways, the enteric nervous system seems to be evolutionarily older than the central nervous system, presumably because food intake and digestion are priorities for simple organisms.

The enteric nervous system uses about twenty different transmitter substances, the most important of which are acetylcholine, vasoactive intestinal polypeptide (VIP), nitric oxide (NO), GABA, and serotonin. Complex networks in the enteric nervous system can learn to adapt to challenges in the absence of CNS control. In Hirschsprung's disease, there is a congenital absence of parasympathetic innervation of the sigmoid colon, which makes the sufferer unable to defecate. Treatment consists of removal of the non-innervated region of the colon. About a year after removing the denervated section, the remaining colon learns to defecate.

#### Questions for repetition

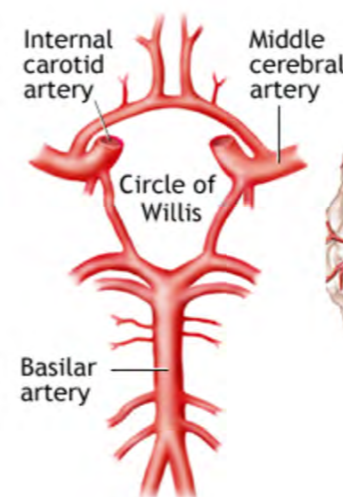
- How can the autonomic nervous system be subdivided?
- Within which spinal cord segments are the sympathetic motor fibers located?
- How are the sympathetic ganglia located in relation to the spinal cord and effector organ?
- Name three functions of the sympathetic and parasympathetic nervous systems.
- Name three neurotransmitters that play a role in the enteric nervous system.

## BLOOD SUPPLY TO THE BRAIN

### The blood supply to the brain

#### Arterial supply

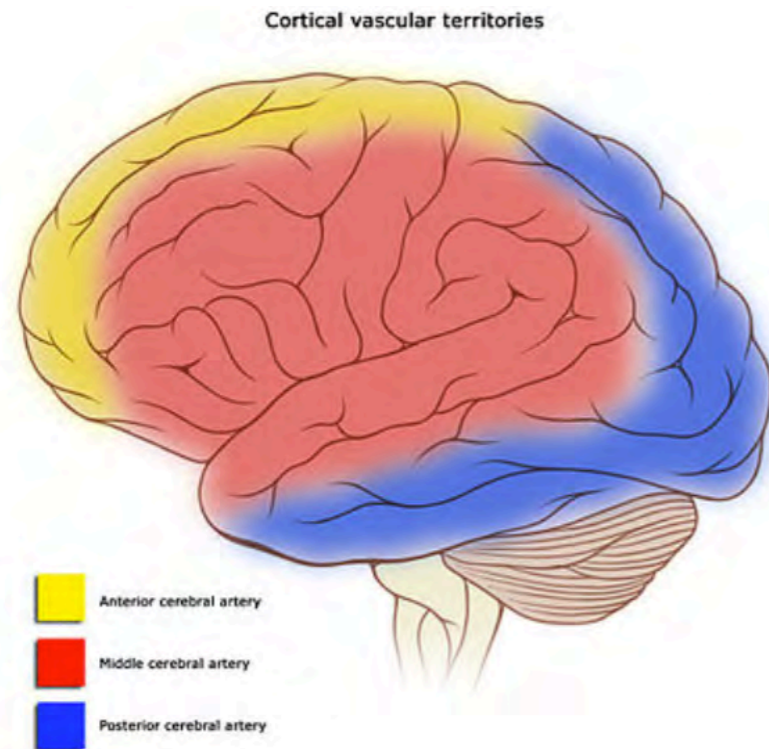
The arterial supply to the brain comes from two internal carotid arteries at the front and two vertebral arteries at the back. Each internal carotid artery divides into a larger middle cerebral artery and a smaller anterior cerebral artery. The two vertebral arteries join to form the basilar artery, which supplies the brain stem. The basilar artery divides to form the two posterior cerebral arteries. The carotid and basilar systems are linked together by small communicating arteries to form an arterial circle (the circle of Willis) at the base of the brain.



***The arterial circle of Willis is formed by the two posterior cerebral arteries (branches of the basilar artery) and branches of the internal carotid artery (the middle cerebral artery, anterior cerebral artery). The posterior and anterior communicating arteries complete the circle.***

The middle cerebral artery supplies most of the lateral surface of the cerebral cortex. The anterior cerebral artery supplies the medial side of the front half of the cortex and a strip around the anterior and superior margin of the lateral cortex. The posterior cerebral artery supplies most of the occipital lobe, including the visual cortex.

The three main cerebral arteries send deep perforating branches to deep cerebral structures (such as the internal capsule) before reaching their cortical branches.

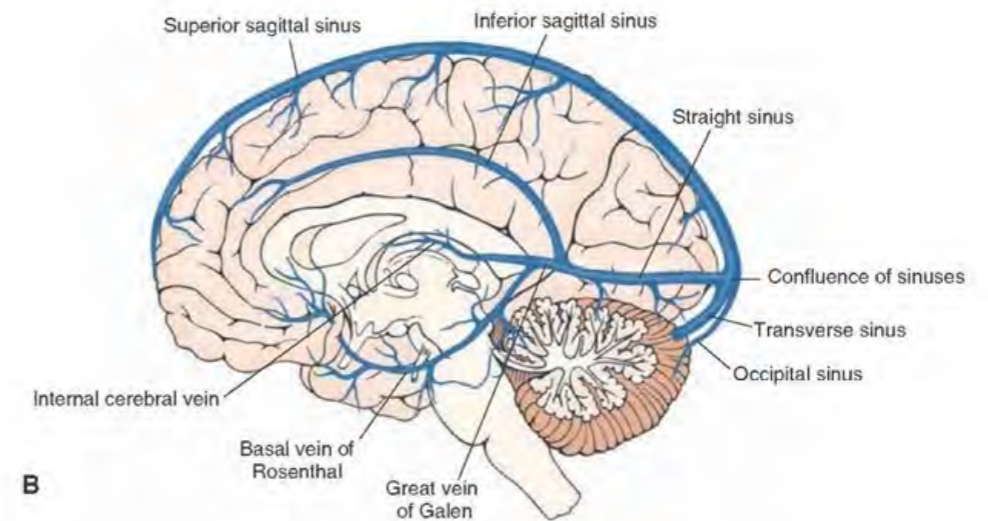
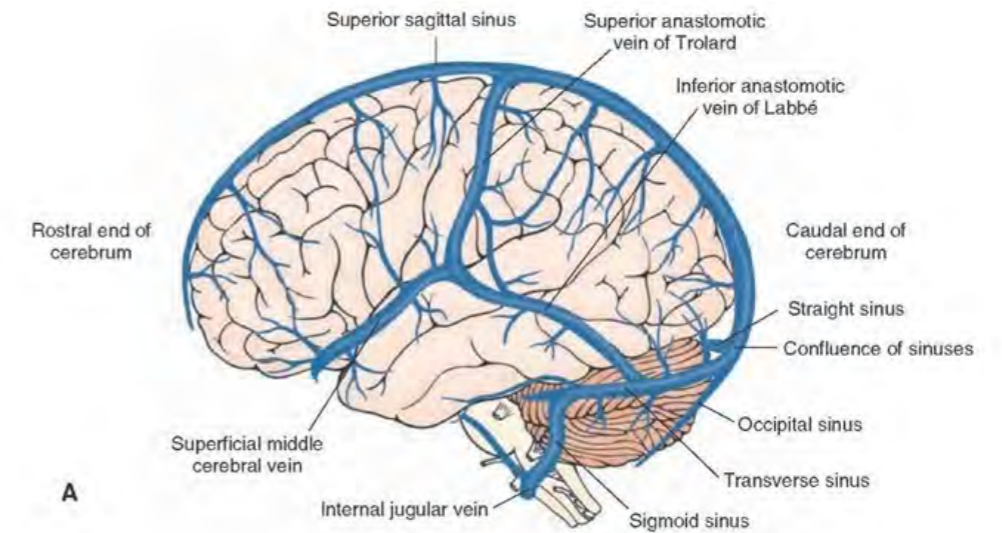


*The arterial supply to the lateral cerebrum by the middle cerebral artery (red), the anterior cerebral artery (green), and the posterior cerebral artery (blue).*

**Venous drainage of the brain**

The veins of the cerebrum end in dural venous sinuses that surround the brain. The dural sinuses are embedded in the dura mater, and they drain into the internal jugular vein.

The venous sinuses also drain the cerebrospinal fluid (CSF) into the bloodstream. The CSF is absorbed into the venous sinuses through arachnoid granulations, which are evaginations of the arachnoid mater. The most prominent dural sinuses are the superior sagittal sinus, the inferior sagittal sinus, the occipital sinus, and the transverse sinus.



*Venous drainage of the brain. The superior sagittal sinus collects blood from the lateral aspect of the cerebral hemispheres. The superior sagittal sinus forms two transverse sinuses, which drain into the internal jugular vein. The Inferior sagittal sinus forms the straight sinus, which joins the junction of the superior sagittal and transverse sinuses.*

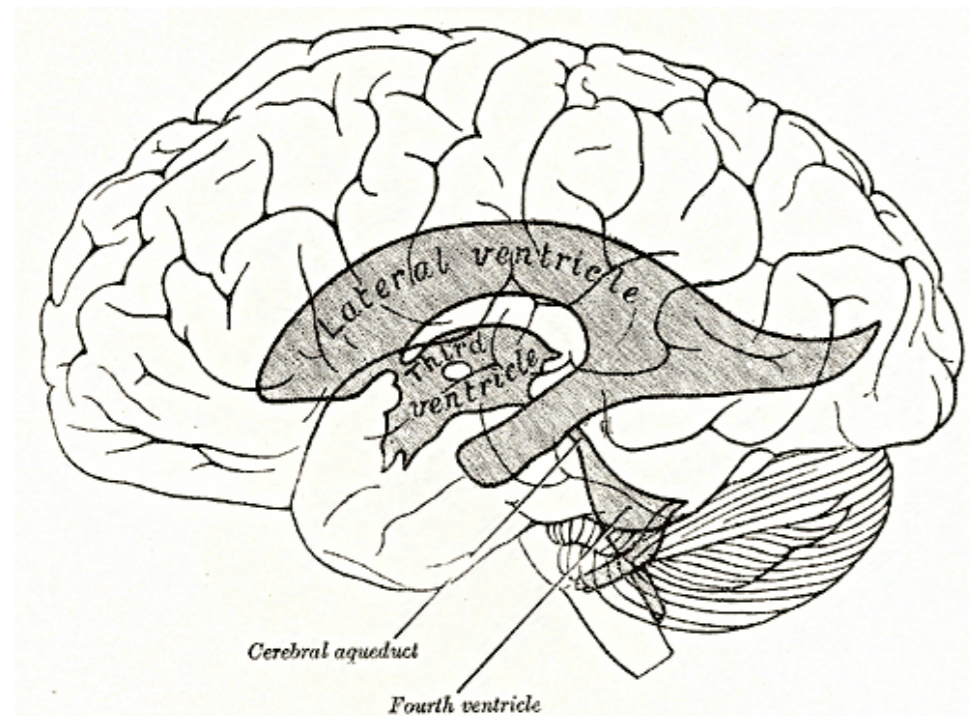
**Questions for repetition**

- Which arteries form the Circle of Willis?
- The speech centers are in the supply area of which larger artery?
- What are the structures called in which the spinal fluid is absorbed into the venous sinuses?

## THE CIRCULATION OF CEREBROSPINAL FLUID

### The cerebrospinal fluid and its circulation

The brain and spinal cord are surrounded by three meningeal layers—a thick dural layer next to the bone, a thin arachnoid layer deep to the dura, and a thin pial layer on the surface of the brain and spinal cord. The space between the arachnoid and the pia (the subarachnoid space) is filled with a clear liquid called cerebrospinal fluid (CSF). The soft structure of the brain makes it vulnerable to mechanical damage; therefore, the cerebrospinal fluid acts as a shock absorber to protect it against injury.



*Overview of the ventricular system; Henry Gray (1918) Anatomy of the Human Body.*

### Circulation

The CSF is manufactured inside the brain by the choroid plexuses of the brain ventricular system. The ventricular system of the cerebrum consists of two lateral ventricles - one inside each cerebral hemisphere. The lateral ventricles drain into the third ventricle, a narrow slit between the two halves of the hypothalamus and thalamus. The CSF then travels along a thin tube in the midbrain called the aqueduct. The aqueduct drains into the fourth ventricle, between the cerebellum and the hindbrain. Finally, the fluid escapes through three holes in the roof of the fourth ventricle to reach the subarachnoid space. Cerebrospinal fluid is reabsorbed into the blood circulation by specialized structures in the walls of large veins that line the inside of the skull.

The main part of the choroid plexus lies in the medial wall of the body and the inferior horn of the lateral ventricle. Nevertheless, groups of choroid plexus cells are present in the roof of the third ventricle and the roof of the lower half of the fourth ventricle as well. If cerebrospinal fluid circulation is blocked, CSF will accumulate in the ventricular system of the cerebral hemispheres. Gradually the cerebral ventricles will be forced to expand, and cells in the cerebral cortex will be killed by compression. This condition is known as hydrocephalus.

### The blood-brain barrier and the circumventricular organs

The blood-brain barrier prevents particular molecules in the bloodstream from reaching the brain's tissues. This system helps protect the brain from bacteria, viruses, and chemical toxins that could cause damage. The blood-brain barrier is created by membrane specializations in the walls of the endothelial cells of the brain capillaries. Water-soluble molecules cannot pass through the cellular membrane of the endothelial cells and so are unable to reach the extracellular fluid of the brain tissues. However, small lipid-soluble molecules can travel through the membrane—a factor that prompted the development of lipid-soluble drugs to reach the brain. The blood-brain barrier is not present in the circumventricular organs of the brain. These are small, specialized areas in the walls of the third and fourth ventricles. Neurons in the ventricular organs are able to monitor the levels of certain chemicals in the bloodstream.

### Questions for repetition

- Where is the spinal fluid formed?
- Describe the flow of spinal fluid.
- In which areas can neurons obtain information about chemical components of the blood?

## STAINING AND IMAGING

### Staining and imaging – Fundamentals

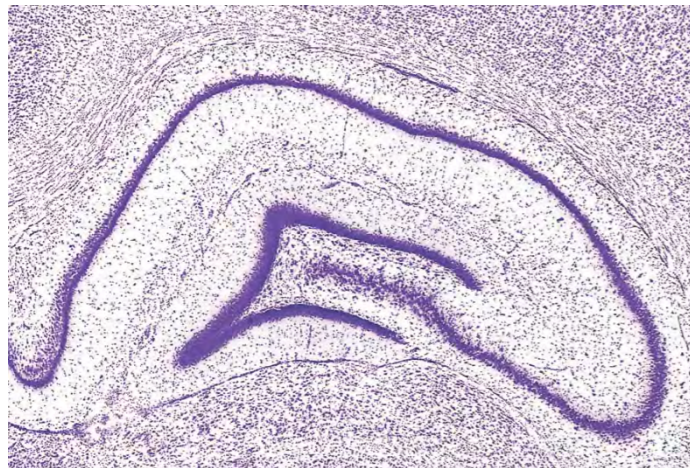
Information about the detailed structure of the brain and spinal cord can be gathered from the microscopic study of thin sections that have been stained to show the presence of nerve cells and their processes.

#### Cutting thin sections

Thin sections can be cut from fresh brain tissue that has been frozen, but in most cases, brain sections are collected from brain tissue that has been preserved with a fixative chemical like formalin. Thin sections are cut with a microtome – a special slicing machine cutting sections ranging from 5 to 100 micrometers ( $\mu\text{m}$ ) in thickness. Formalin-fixed tissue is usually prepared for sectioning by embedding it in paraffin wax or celloidin, but it can also be frozen before sectioning.

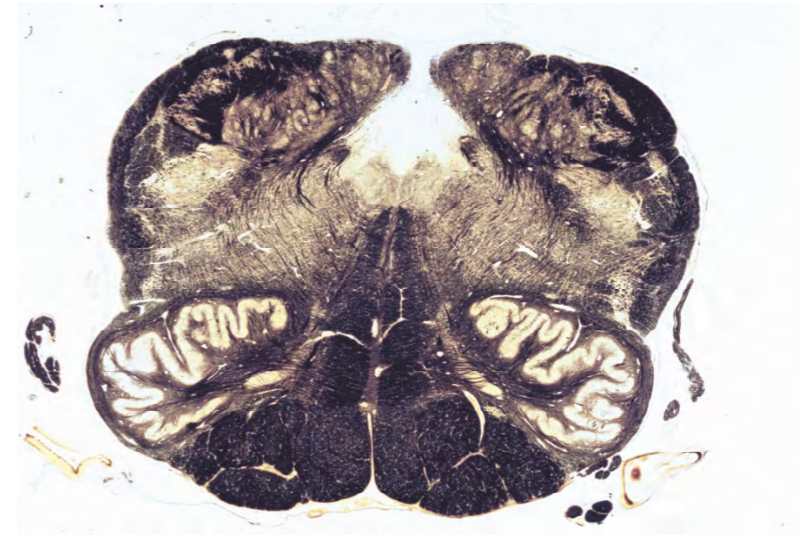
#### Staining brain sections

The two classic staining methods are the Nissl stain for staining neuron cell bodies and stains for myelinated axons. Nissl stains use a variety of dyes, such as thionin and cresyl violet, to reveal details of the cell body and nucleus of neurons and glia. The Nissl stain is most intense in nucleoli and in the rough endoplasmic reticulum of neurons.



*In this Nissl-stained section of rat hippocampus, some neurons are packed tightly together, so they seem to form a continuous line of violet color. In other areas, cells can be seen like grains of sand scattered over the image. It is impossible to distinguish between small neurons and glia at this magnification clearly.*

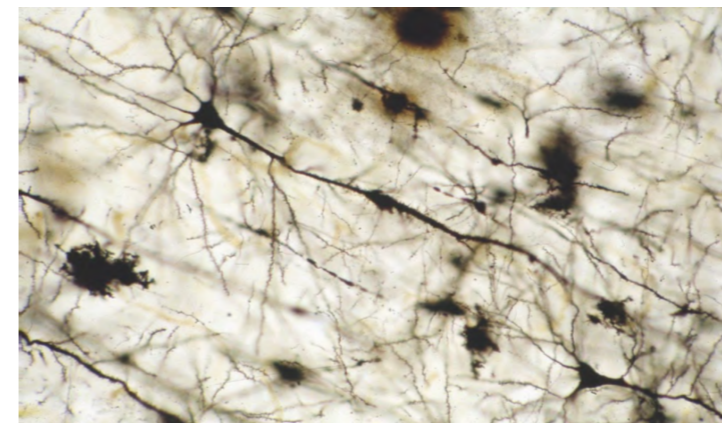
Stains that show the presence of myelin have been very widely used in the study of human brains for over a century. The stains can be applied to histological sections and thick slices of the human brain. The myelin stains most commonly used are the Weigert or Luxol fast blue methods.



*A coronal section of human brain stem stained with the Weigert method for myelin. Large tracts like the pyramids and the medial lemniscus stain darkly, whereas cellular areas like the inferior olive are unstained.*

#### The Golgi method

A disappointing feature of Nissl stains is that they only show the presence of neuronal cell bodies. However, Camillo Golgi brilliantly solved this problem at the end of the nineteenth century. Golgi developed a remarkable silver stain that revealed details of dendrites and axons and cell bodies. The cells and their processes are stained black against a golden background. The Golgi stain was so useful because it only stains about one percent of the neurons in the section being examined so that individual neurons can be seen in isolation. If all neurons were stained, the image would be solid black. The use of this stain launched a revolution in the understanding of brain anatomy pioneered by the Spaniard Ramon y Cajal.



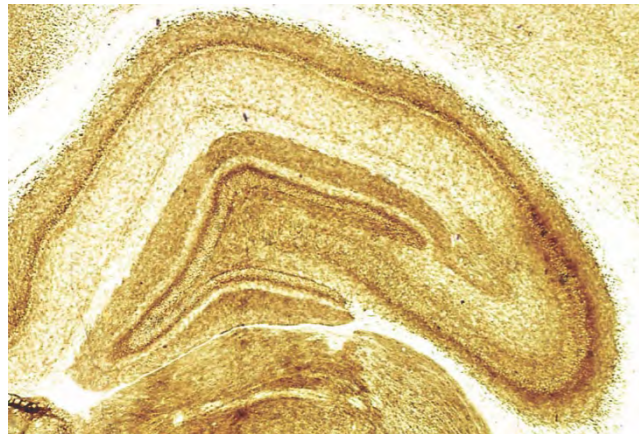
*This is a thick section of the cerebral cortex stained with the Golgi method. The stain shows details of the cell body, dendrites, and axon of a large pyramidal cell in the lower half of the image.*

Until the middle of the twentieth century, almost all that was learned about brain structure came from the study of Golgi-stained sections. The next phase of neuroanatomical research was launched by using histochemical stains and methods for tracing neuronal connections.

#### Histochemical staining

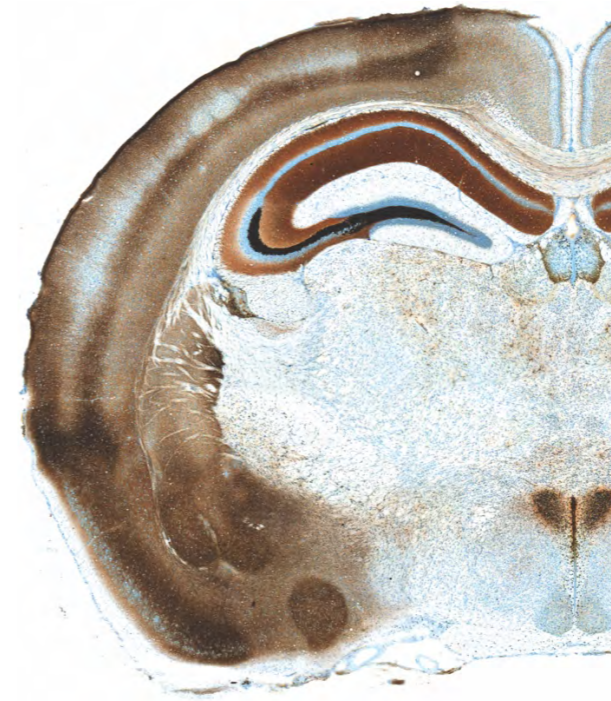
Histochemical stains are used to mark specific cellular components of neurons or glia, followed by applying dyes attracted to the marked elements. Many histochemical methods are

aimed at detecting the presence of enzymes, and these techniques usually work best on unfixed or lightly fixed sections in which the enzymes are undamaged. Acetylcholinesterase (AChE) staining uses s-acetylthiocholine iodide and ethopropazine to deposit a brown product wherever the acetylcholinesterase enzyme is present and active. Since many neurons have receptors for acetylcholine, this technique can be used to characterize regions of strong cholinergic activity and differentiate between different areas in the brain. Motor neurons contain large amounts of acetylcholinesterase, and the AChE stain is very effective in showing their distribution in the brain stem and spinal cord. The value of AChE staining can be seen in the adjacent AChE section of the hippocampus in a rat brain section. The stain reveals a remarkable level of detail in the layers and sub-layers of the hippocampus.



*A section of rat brain stained to show the presence of the enzyme acetylcholinesterase in the hippocampus*

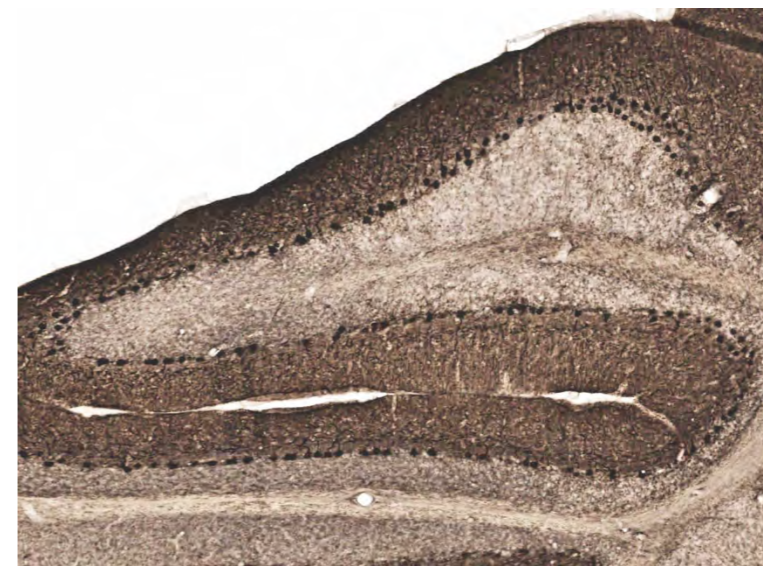A variety of other histochemical stains have been developed to detect the presence of other transmitter substances, such as nitric oxide. Zinc and other metal stains are based on methods that deposit silver or fluorescent dyes around ions of zinc and other heavy metals. The Timm-Danscher silver stain is commonly used to show the presence of zinc. Zinc is used in DNA regulation and synaptic plasticity, as well as other cellular signaling. That is why zinc stains can show long-term activity patterns and responses to change.



*This is a coronal section of rat brain stained with the Timm-Danscher method. The dark silver deposits show the regions that contain high concentrations of zinc.*

### Immunohistochemistry

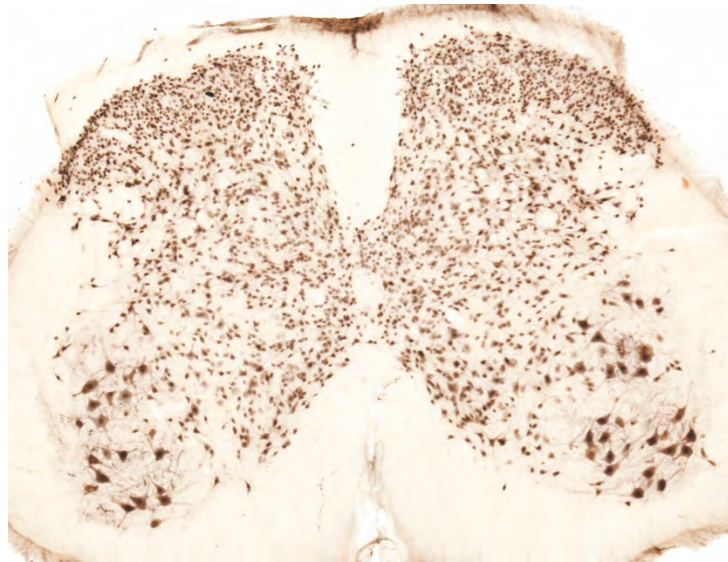
Immunohistochemical stains use antibodies to detect the presence of particular proteins in neurons. The main challenge for immunohistochemistry is ensuring that antibodies only bind to the protein of interest and no other related proteins. Calcium-binding proteins (such as calbindin, calretinin, and parvalbumin) are often restricted to particular cell groups, and immunohistochemical methods to detect these proteins are very useful in anatomical mapping studies.



*This is a section of the cerebellum of a marmoset monkey in which the presence of the calcium-binding protein calbindin has been revealed by immunohistochemical staining. In this section, the Purkinje cell bodies are stained forming a line between the dark brown stained molecular layer and the light brown stained granule cell layer.*



Neurofilaments are structural proteins present in certain types of neurons. The monoclonal antibody SMI-32 is widely used because it can demonstrate the presence of a particular neurofilament protein in different structures of the nervous system. NeuN is an antibody specific to the *NeuN* nuclear protein expressed by nearly all neurons and never in glial cells. A few neuron types (such as the cerebellum's Purkinje cells) do not express the NeuN protein and are therefore unlabelled.

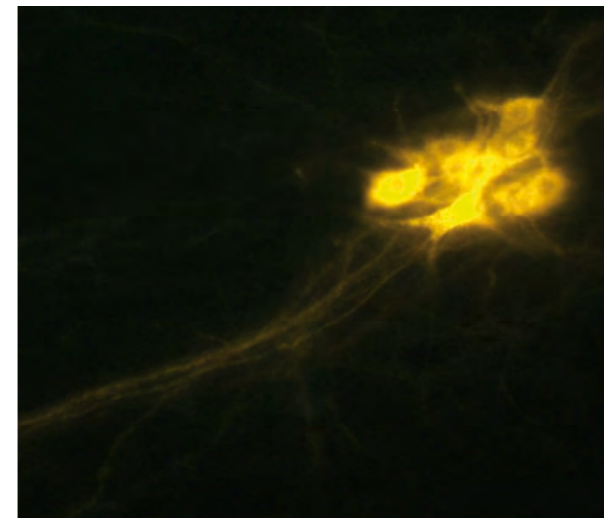


***A transverse section of mouse spinal cord showing the presence of NeuN antibody. The cell bodies and dendrites of motor neurons in the ventral horn are clearly stained. In the dorsal horn, the stain shows the presence of many tiny neurons. We know these are neurons rather than glia because glial cells do not contain the NeuN protein.***

Glial protein markers are used to distinguish particular glial cell types. GFAP (glial fibrillary acidic protein) identifies astrocytes, and other antibodies are used to mark proteins specific to microglia and oligodendrocytes.

### Tracing connections in the nervous system

Until about 1970, the most effective way of tracing connections in the nervous system was a silver stain for degenerating axons. When a particular part of the nervous system is damaged, the degenerating axons from the damaged neurons can be stained with a silver stain first developed by Nauta at MIT around 1950. This technique was the mainstay of tracing studies before introducing modern tracing studies, such as those using horseradish peroxidase (HRP), that use normal axonal transport mechanisms. HRP uses retrograde axonal transport to mark cell bodies after it is picked up into axon terminals. Still, many newer tracers, such as cholera toxin B, use anterograde transport to show the terminal distribution of particular axons.

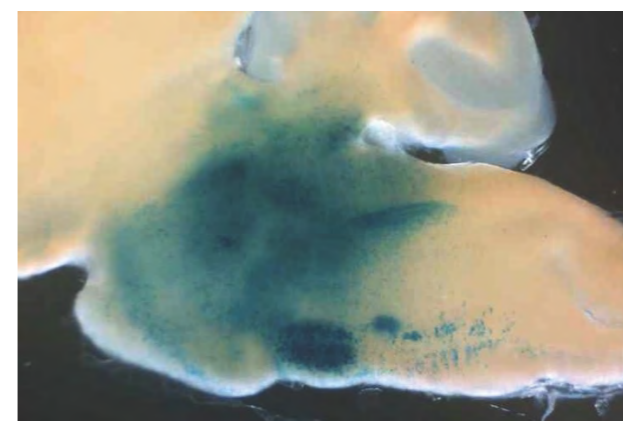


***Retrograde tracing. This image shows a group of neurons showing the presence of the retrograde tracer DiI which had been injected in the region of the axon terminals of these neurons. The marker was carried by retrograde transport along the axons to reach their parent cell bodies***

The value of tracing data depends on the accurate localization of the point where the tracer is delivered. The exact identification of the desired delivery point is generally based on the use of a stereotaxic atlas. Stereotaxic atlases are three-dimensional maps that can be used to define the location of nuclei and tracts with reference to these landmarks, such as bregma, that can be located during surgery. Some tracers can be detected in target areas within less than a day, but others take weeks to reach their destination. Tracers can be detected with fluorescence or with histochemical techniques.

### Molecular genetics

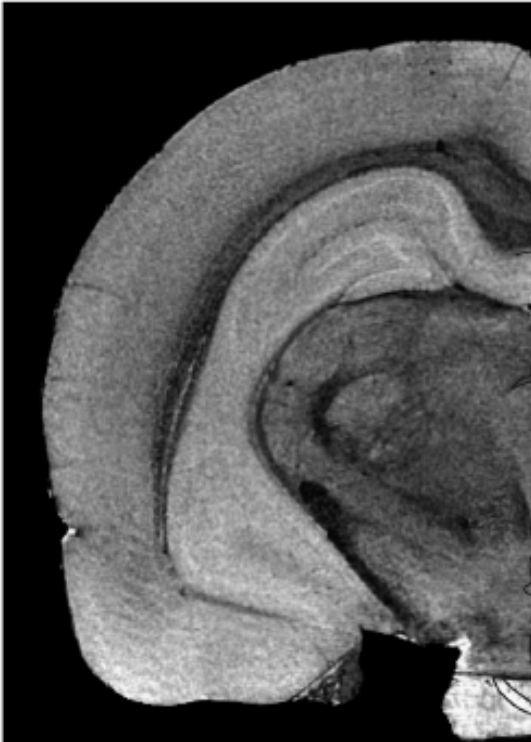
The ability to target genes in mice was developed in the 1980s by Nobel Prize winners Capecchi, Evans, and Smithies. Gene targeting can knock-out genes or insert (knock-in) new genes into developing cells. Gene knock-ins and knock-outs use techniques that can add a functioning gene to the organism or disable a gene it already has so that its effect on the animal can be tracked through development and adulthood.



***A sagittal section of mouse brain showing the expression of the gene Phox2b. Phox2b is strongly expressed in the facial nucleus (large oval area near the ventral margin).***

### MRI imaging

A major breakthrough in the 1990 led to the use of magnetic resonance (MRI) for imaging the brain. MRI relies on the ability to excite specific types of atoms (usually hydrogen in water molecules) and to image them systematically. This allows detailed three-dimensional maps to be obtained. MRI resolution depends on the strength of the magnetic field used. Early MRI imaging used field strengths of 1 - 3 Tesla, which yielded a resolution of 1 - 3mm, but new small-volume MRI scanners use 16 Tesla fields, which can resolve structures in the 20 -50  $\mu\text{m}$  range.



*An image of a rat brain obtained with a 9 Tesla MRI scanner.*

### Questions for repetition

- What is stained during myelin staining?
- What stain can be used to stain myelin?
- Which neurons are particularly rich in AChE?
- What axonal transport mechanism do many tracers use?